

# EVALUATION AND TREATMENT OF COCCYX PAIN

Dr Stephen Sandler PhD DO

## Introduction

- Coccyx pain aka coccydynia or coccygodynia is a common problem, however articles stating the prevalence of the condition have not been found despite extensive searching.
- In my practice I have seen 50 -60 cases each year over the last three years often referred in by other osteopaths who feel that their training in this area was weak and thus they refer to a “specialist” in the area.

- It has been estimated at 1% of any population report back pain part of which is coccyx pain
- This type of pain occurs five times more frequently in women than in men
- Coccydynia does not target a certain type of ethnicity or race

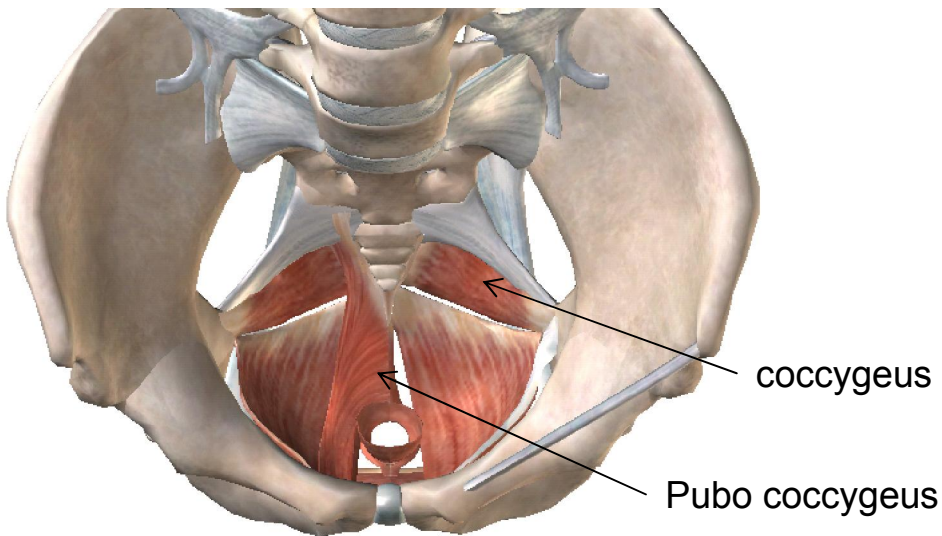
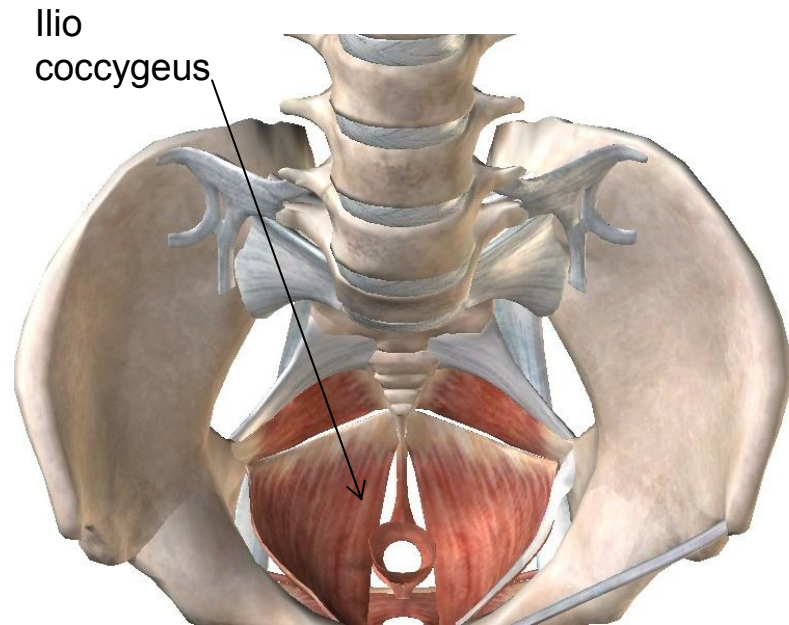
# The Anatomy

## Muscle and ligament attachments

The coccyx is part of the weight-bearing tripod structure which act as a support for a the sacrococcygeal symphysis when sitting.

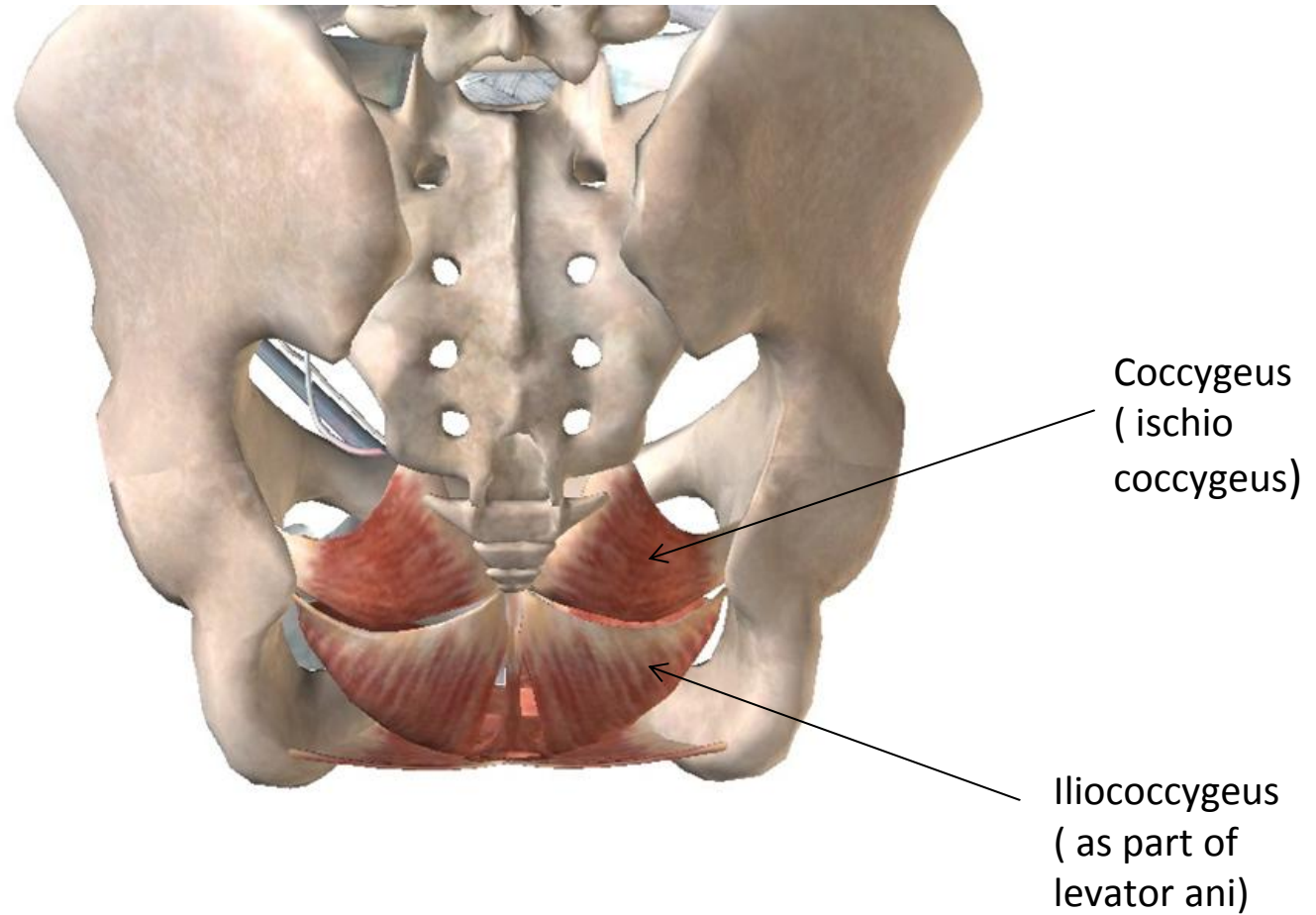
When a person sits leaning forward, the ischial tuberosities and inferior rami of the ischium take most of the weight, but as the sitting person leans backward, more weight is transferred to the coccyx. *This can be a differential diagnostic question when taking a case history.* However pain can occur on rising from sitting as the centre of gravity is transferred posteriorly and weight comes again to the flexed traumatised coccyx.

-

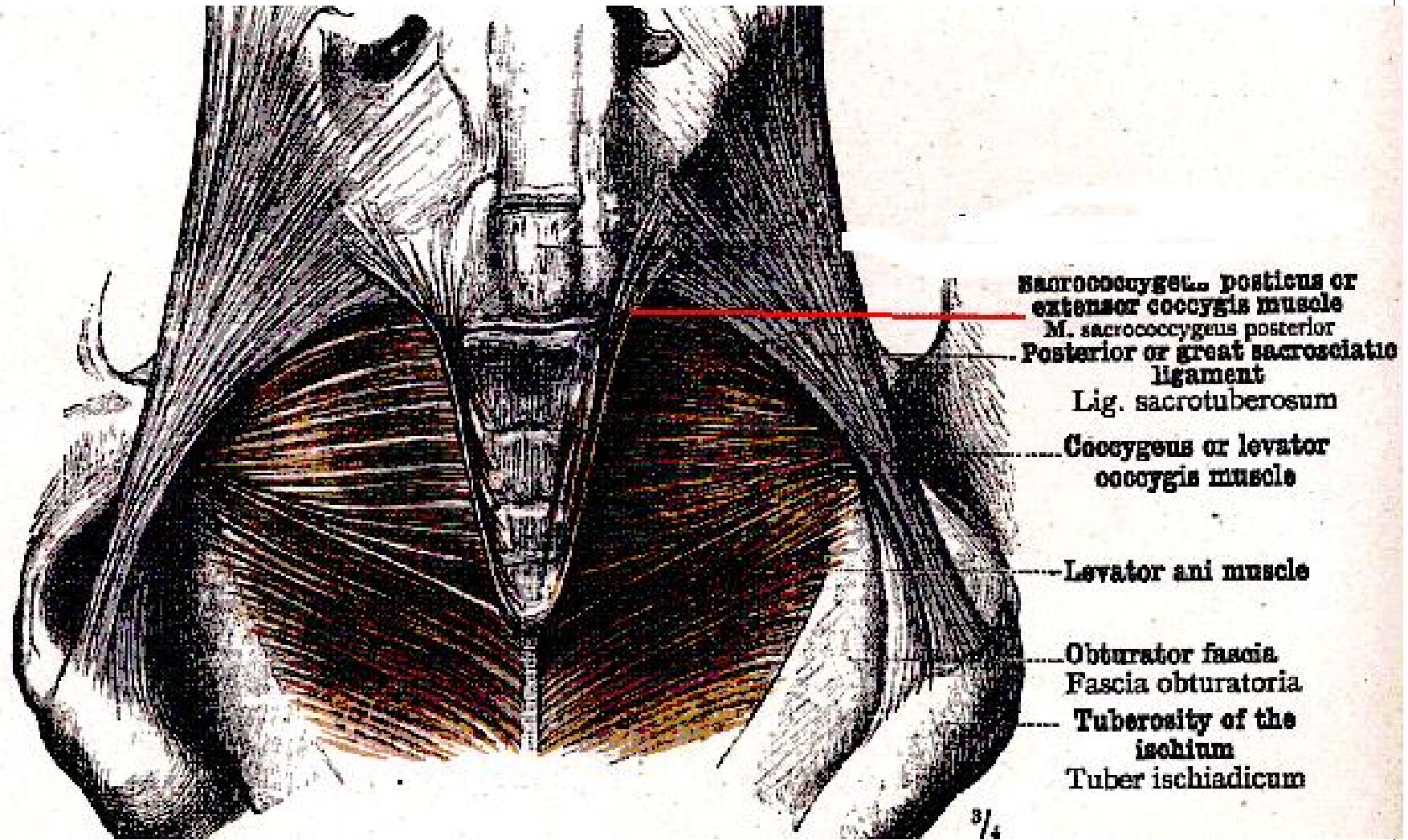


- The anterior side of the coccyx serves for the attachment of a group of muscles important for many functions of the pelvic floor (i.e. defecation, continence): the levator ani muscle, which include coccygeus, iliococcygeus, and pubococcygeus. Through the anococcygeal raphe, the coccyx supports the position of the anus. Attached to the posterior side is the gluteus maximus which extends the thigh during walking.

# The Pelvic floor and the Coccyx seen from behind



Extensor Coccygeus the only picture to be found  
<http://hdl.handle.net/10504/17104>



MUSCULUS SACROCOCYGEUS POSTERIOR, SACROCOCYGEUS POSTICUS OR EXTENSOR  
COCYGIS MUSCLE

# The Ligaments of the coccyx

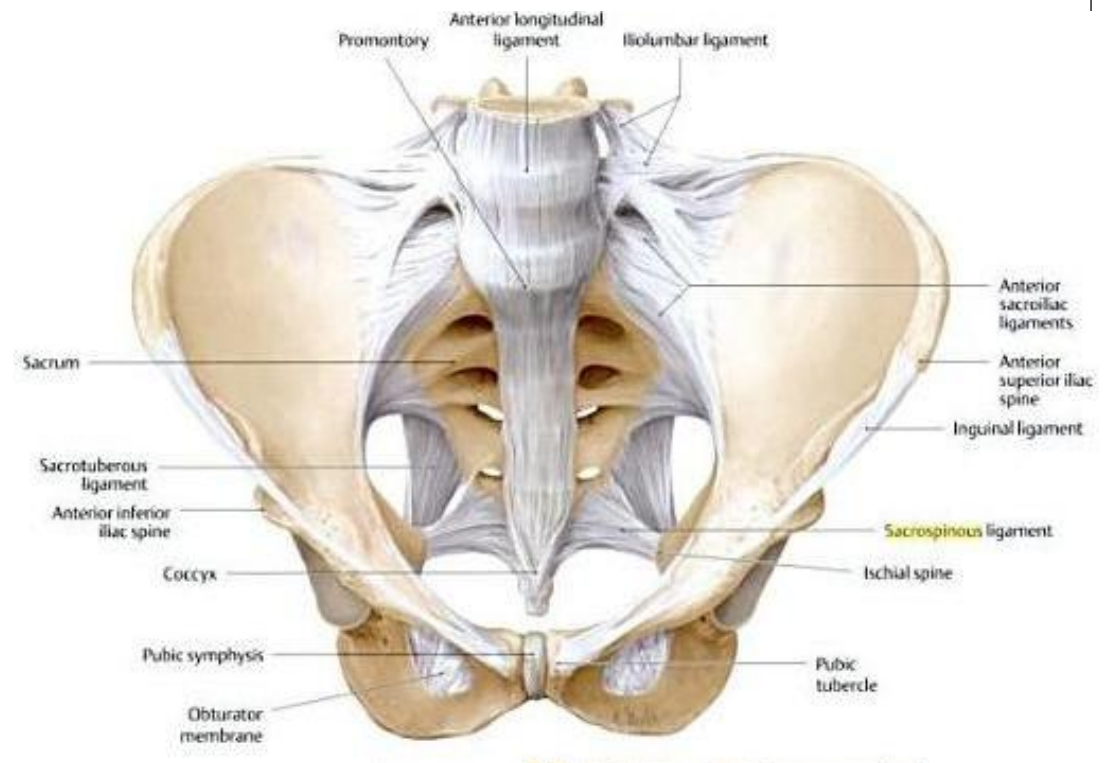
Many ligaments attach to the coccyx.

The anterior and posterior sacrococcygeal ligaments are the continuations of the anterior and posterior longitudinal ligaments that stretch along the entire spine.

The lateral sacrococcygeal ligaments complete the foramina for the last sacral nerve.

Some fibers of the sacrospinous and sacrotuberous ligaments (arising from the spine of the ischium and the ischial tuberosity respectively) also attach to the coccyx.

An extension of the [pia mater](#), the [filum terminale](#), extends from the apex of the [conus](#), and inserts on the coccyx





# Differential Diagnosis of Coccydynia

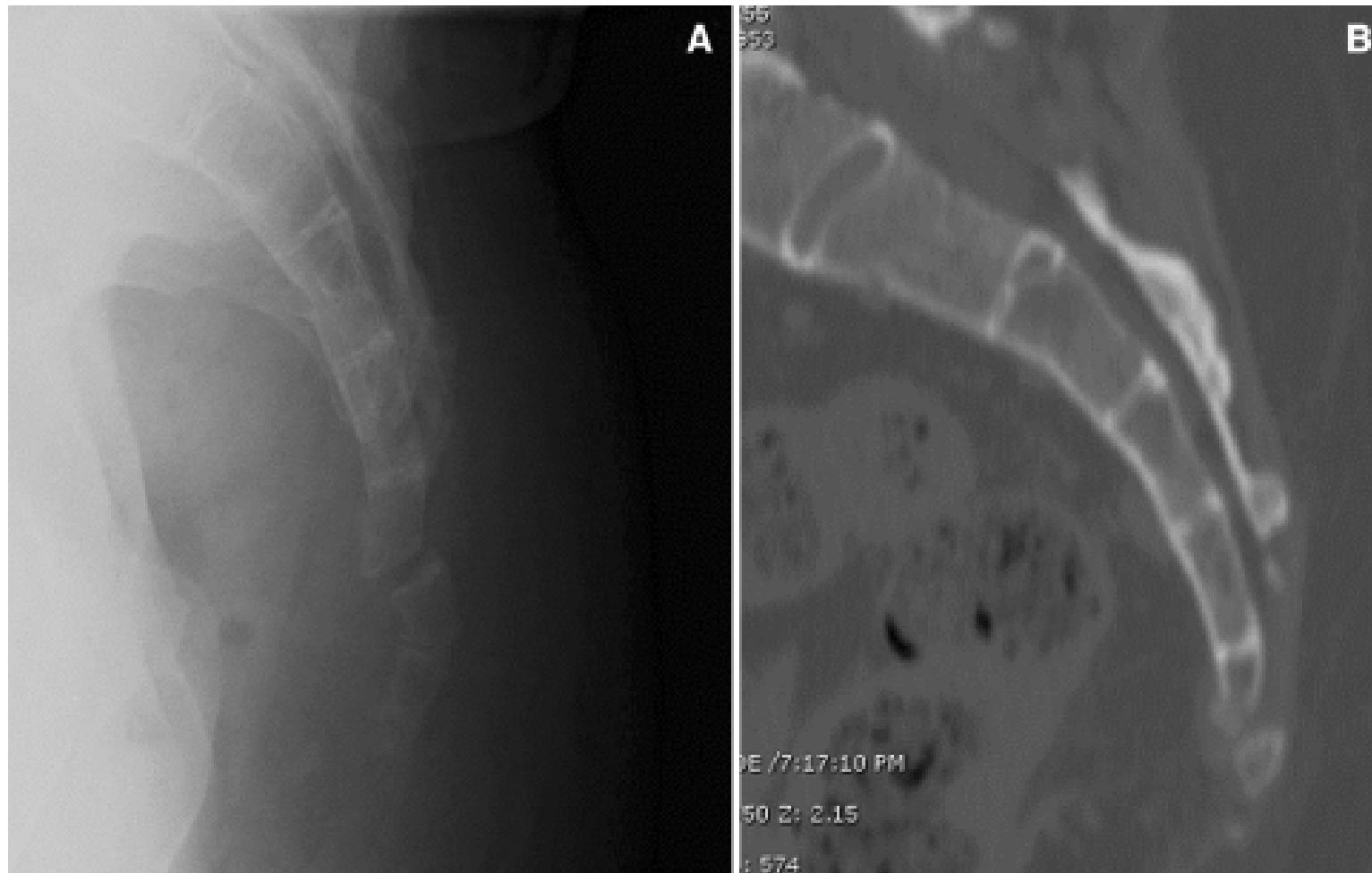
- The most important differential diagnostic tool is still the history.
- The most important consideration in the history has to be the is it coccygeal pain or not?
- **The most important question has to be trauma or not**

# History taking

- Coccygeal trauma

- The commonest trauma is falling on the buttocks
- i.e. Falls on ice
- Skiing
- Falls from horse
- Also prolonged bike rides especially if it mountain biking,
  - Or speed bumps and bad road surfaces !!
    - We are looking for a fracture and if in doubt send the patient for a lateral coccygeal X Ray and if possible a dynamic view standing

Lateral radiograph (a) and sagittal CT reconstruction (b) demonstrating a fractured coccyx in a patient who was diagnosed with coccydynia following a ground-level fall 6 months earlier



# History Taking

- Weight bearing
  - The differential diagnosis is disc or coccyx
    - Especially hard surfaces
    - Getting up from a soft chair can indicate either disc disease or coccygeal pain
    - Is it an SIJ problem rather than a coccyx especially post partum
    - Do not forget referred pain from the facet joints in the LS segment
    - Patients sit on one buttock to avoid the painful coccyx

# History Taking

## Condition and signs / symptoms

- Lumbar spondylosis/disc herniation
- Pain is relieved by sitting.
- Pain and/or tenderness may involve the sacrum or lumbar spine, without specific tenderness of the coccyx.
- No pain or tenderness on palpation of coccyx or rectal examination.

## Medical testing

- Injection of corticosteroid around the dorsal surface of the coccyx does not relieve pain, indicating pain is referred.
- MRI of lumbosacral spine may reveal the site of degenerative disc disease or disc herniation.

# History Taking

## Conditions signs and symptoms

- [Levator ani syndrome](#)
- Also known as puborectal syndrome, levator spasm, or pelvic floor myalgia.
- This category may include some cases of idiopathic coccygodynia.
- Dull ache or pressure sensation in the rectum, exacerbated by prolonged sitting or supine position, which may last hours to days.
- Tenderness of puborectalis muscle on rectal examination.

## Medical testing

- Although some studies have shown increased anal canal pressure and correlated pain relief with a decrease in pressure, other authors have discouraged its routine use, citing unreliability in its diagnostic and predictive value.

# History Taking

## Condition and signs / symptoms

- Alcock's canal syndrome
- Also known as pudendal canal syndrome or pudendal nerve entrapment.
- Unilateral or bilateral burning, prickling, stabbing, or numbness in the perineum, external genitalia, or scrotum.
- Pain is worse with sitting and there is a sense of a foreign object in the urethra, rectum, or vagina.

## Medical testing

- Diagnosis is essentially clinical.
- MRI reveals normal anatomy, or intercurrent disease unrelated to the diagnosis, or occasionally may reveal a nerve sheath tumour.
- Pudendal nerve motor latency studies (nerve conduction studies) are usually normal, as sensory fibres are affected preferentially.
- Diagnostic nerve block, consisting of anaesthetic infiltration within the pudendal canal, results in pain relief for the duration of anaesthesia, but may be technique dependent.

# History Taking

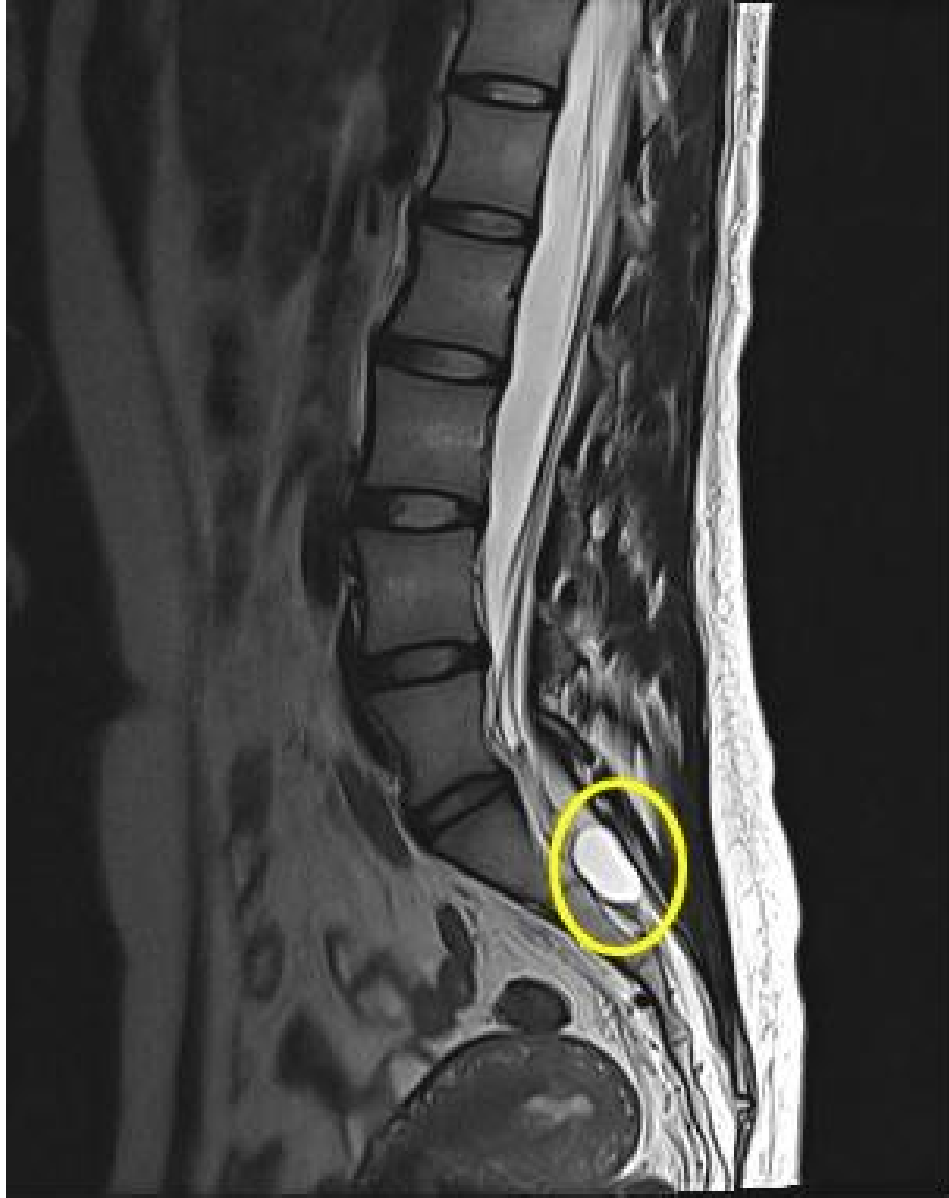## Condition signs or symptoms

- Tarlov cyst
- Rare cause of coccygodynia.
- Sacral perineural cysts may rarely present with coccygeal pain.
- May be accompanied by urinary disturbance and pain in the groin region.

## Medical testing

- MRI of the sacrum reveals nerve root cysts of CSF density, bright on T2 weighted sequences.
- CT may reveal enlargement of the sacral foramina or thinning of the sacral lamina around the cyst.
- May or may not fill on contrast myelography.
- No relief of pain on coccygeal injection with corticosteroid





# Pelvic Pain or Coccygeal Pain?

- Is there bleeding?
  - The presence of bleeding with pain suggests an anal fissure,
  - hemorrhoids,
  - carcinoma,
  - rectal prolapse,
  - and intussusception.

# Pelvic Pain or Coccygeal Pain?

- Is there a mass?
  - The presence of rectal pain along with a mass would suggest
  - internal and external hemorrhoids,
  - rectal carcinoma,
  - and perirectal or ischiorectal abscesses.

# Pelvic Pain or Coccygeal Pain?

- However, in females,
- masses in the cul-de-sac ( pouch of Douglas),
  - such as an acute salpingitis,
  - ectopic pregnancy,
  - or endometriosis,will cause rectal pain.
- If in doubt refer to gynaecologist for expert PV assessment

# Pelvic Pain or Coccygeal Pain?

- In males,
  - prostatic abscess,
  - foreign bodies,
  - and seminal vesiculitismay cause rectal pain.

# Pelvic Pain or Coccygeal Pain?

- Is there a purulent discharge?
  - Fistula in ano,
  - perirectal abscess,
  - ischiorectal abscess,
  - and submucous abscessmay cause a purulent discharge.

# PROTOCOL FOR EXAMINATION AND TREATMENT PER RECTUM

# Ethical Considerations

- You must read the General Osteopathic Council document “Fitness to Practice”. This is the minimum standard that the register demands and is the document by which you will be prosecuted if you fall foul of the regulations.
- 5 minutes explanation beforehand is better than time spent in apology afterwards



# Ethical Considerations

- There is no such thing as implied consent, you either ask and receive positive consent or you do not proceed

## Indications for PR investigation and treatments

- Cases where there has been direct trauma to the area
- Cases where you suspect trauma post partum after a long or difficult labour
- Cases of prostatic disease in elderly men
- Cases where there has been surgery to the pelvic floor in either sex where there has been scarring and thus a drawing up of the pelvic floor that can flex the sacro coccygeal junction

# Contra indications to PR investigation and treatments

- Lack of express permission
  - Has the patient understood what you want to do?
  - Are they compos mentis?
  - Is it a child ? If so do you have the parent or guardian's permission?
- Large piles or anal fissures
- Ano rectal carcinoma
- Excess fear or pain in anticipation of the procedure

# Examination

- Standing Exam
  - Static
  - Active movements
    - Observation and palpation both actively and passively standing to exclude other structures
    - Weight bearing tests +ve / -ve ??
    - Is this referred pain or real coccydnia?

# Examination

- Sitting tests
  - Slump test
  - Direct test to the coccyx.
    - This is a sensitive area and you MUST get permission before you start.
    - You MUST use a plastic skeleton or at least a diagram to explain what you are going to do before you do it. The only when you have heard the positive permission given can you carry on.
    - If in doubt DO NOT CONTINUE

# Examination

- Supine Examination
  - Hip rotation for pelvic floor tone
  - SI joint testing
  - Ischial Tuberosity muscle tone testing
  - Get patient to actively contract the tone of the pelvic floor and assess

# Examination

- Prone examination
  - Ask permission to reveal the buttock cleft
  - Palpate PSIS PIIS
  - Identify the SC junction and palpate from above and laterally before directly.

# Summary

1. Does the history reveal the likelihood of a coccygeal problem or is this an undiagnosed LS SIJ or Hip problem or even an unrelated pathology?
2. Does the standing exam confirm or deny the suspicions raised by the history?
3. Does the supine exam show hip disease or SIJ pain . What does the pelvic floor exam reveal when you compare one side to the other?
4. Does the prone exam suggest pain coming directly from the coccyx and is there increased muscle tone in the muscles relating to the coccyx on one side or the other?
5. Does the sitting exam give you the final proof you need?



# The Technique

- The technique of choice is going to be a Functional Technique done with the patient in the side lying position.
  - Hypothesis
  - Test
  - Prove the hypothesis
  - Treat
  - Retest

# The Test

- Ask the patient to sit on the plinth with their back towards you
- You should stand on the non painful side, if the pain is central then you should stand on the side of the non dominant buttock
- With one hand around their shoulders side bend the patient towards you
- With the index finger of the other hand at the sacro-coccygeal junction move the patient into full flexion and then back into extension.
- As they return to the midline use the index finger to hyper flex the s/c junction. Any increase in pain is a positive response to the test and an indication that the coccyx is flexed and needs an internal manipulation

# The technique

- The osteopath uses gloves on both hands
- Ask the patient to lay with the painful side up.
- They lower their underwear to the knees. There is no need to remove it completely.
- They hyper flex the knees
- With one hand you separate the buttocks and inspect the anus
- Are there any piles fissures or other lesions ? If so be careful not to disturb them

- Place a little lubricant gel on your index finger and place at the anus.
- DO NOT PUSH AGAINST THE ANUS IT WILL PUSH BACK!!
- Gently press against the anus with the index finger and it will relax allowing your finger to penetrate.
- The other fingers of the hand should be clenched so that the knuckles can contact the perineum.
- The index finger inside the rectum moves up all the way to the s/c junction. This is done with the rest of the hand pushing against the perineum. It is a long way up, right to the end of the finger. When you reach the sacrum come down a little way.
- The external thumb is at the s/c junction and when the internal finger arrives you should be able to grasp the coccyx between the external thumb and the internal finger.

- The usual parameters apply for functional technique
- F/E
- Lat Flex Right and left
- Rotn Right and Left
- Translation A/P
- Translation Lateral
- Cephalad and Caudad.
- Look for ease and bind in each parameter

- There are two phases to functional technique
- The investigation phase
- Pause
- The release phase

- Look for ease and bind and hold the ease parameters until they are all identified and stacked up.
- Hold this phase for 20 seconds and then ask the patient to breath out and allow the tissues to release and unwind passively
- The tissues should feel soft and relaxed at the end of the technique.
- At this point grasp the coccyx between the internal and the external fingers and hold it tight.
- Ask the patient to hyper extend their knees and hips and roll back towards you.
- The coccyx now comes back into extension without you having to pull it in any way.
- Now ask the patient to flex again and the coccyx has been replaced

- Gently withdraw the internal finger ,slowly and carefully. The anal sphincter will clean the finger of most of any faecal matter.
- Inspect for blood , there should be none.
- Give the patient some tissue to wipe their own bottom .
- They pull their underwear up and sit.
- They should now be able to rock on their buttocks if the technique has been successful.



- Success rates of complete pain relief are common. Certainly most people are 90% symptom free within a few days.
- Some will need a second manipulation a week later.
- Approx 10% will feel little effect and the coccyx reverts to a flexed and side bent position.
- A third manipulation is rarely used.
- If the coccyx has returned it is an indication that the posterior S/C ligaments are torn and need prolotherapy or a cortico steroid injection.
- It may be that coccygeal amputation is the only option of choice if injections fail.

## Other ways of treating coccygeal pain

- Invariably the patient will have seen the doctor first and will have been offered the following
  - nonsteroidal anti-inflammatory agents (NSAIDs) and other analgesics,
  - reduced sitting,
  - donut pillow use and other postural adjustments,
  - physical therapy.

- They may have been offered a a PR for differential diagnosis and rarely for treatment.
- This study from way back in 1976 is often quoted as a reference source

## The treatment of chronic coccydynia with intrarectal manipulation: a randomized controlled study.

[Maigne JY<sup>1</sup>](#), [Chatellier G](#), [Faou ML](#), [Archambeau M](#).

- [Spine \(Phila Pa 1976\)](#). 2006 Aug 15;31(18):E621-7.
- **The treatment of chronic coccydynia with intrarectal manipulation: a randomized controlled study.**
- [Maigne JY<sup>1</sup>](#), [Chatellier G](#), [Faou ML](#), [Archambeau M](#).
- **STUDY DESIGN:**
- Randomized open study.
- **OBJECTIVE:**
- To evaluate the efficacy of intrarectal manual treatment of chronic coccydynia; and to determine the factors predictive of a good outcome.
- **SUMMARY OF BACKGROUND DATA:**
- In 2 open uncontrolled studies, the success rate of intrarectal manipulation of the coccyx was around 25%.
- **METHODS:**
- Patients were randomized into 2 groups of 51 patients each: 1 group received three sessions of coccygeal manipulation, and the other low-power external physiotherapy. The manual treatment was guided by the findings on stress radiographs. Patients were assessed, at 1 month and 6 months, using a VAS and (modified) McGill Pain, Paris (functional coccydynia impact), and (modified) Dallas Pain questionnaires.

## The treatment of chronic coccydynia with intrarectal manipulation: a randomized controlled study.

[Maigne JY<sup>1</sup>](#), [Chatellier G](#), [Faou ML](#), [Archambeau M](#).

- **RESULTS:**
- At baseline, the 2 groups were similar regarding all parameters. At 1 month, all the median VAS and questionnaire values were modified by -34.7%, -36.0%, -20.0%, and -33.8%, respectively, in the manipulation group, versus -19.1%, -7.7%, 20.0%, and -15.7%, respectively, in the control (physiotherapy) group (P = 0.09 [borderline], 0.03, 0.02, and 0.02, respectively). **Good results were twice as frequent in the manipulation group compared with the control group, at 1 month (36% vs. 20%, P = 0.075) and at 6 months (22% vs. 12%, P = 0.18).** The main predictors of a good outcome were stable coccyx, shorter duration, traumatic etiology, and lower score in the affective parts of the McGill and Dallas questionnaires.
- **CONCLUSIONS:**
- We found a mild effectiveness of intrarectal manipulation in chronic coccydynia.

- The following study in 1991 showed the effectiveness of adding injections to the therapeutic regime

- [J Bone Joint Surg Br.](#) 1991 Mar;73(2):335-8.
- **Coccydynia. Aetiology and treatment.**
- [Wray CC<sup>1</sup>](#), [Easom S](#), [Hoskinson J](#).
- [Author information](#)
- **Abstract**
- A five-year prospective trial involving 120 patients was undertaken to investigate the aetiology and treatment of coccydynia. The cause lies in some localised musculoskeletal abnormality in the coccygeal region. Lumbosacral disc prolapse is not a significant factor. The condition is genuine and distressing and we found no evidence of neurosis in our patients. Physiotherapy was of little help in treatment but 60% of patients responded to local injections of corticosteroid and local anaesthesia. **Manipulation and injection was even more successful and cured about 85%.** Coccygectomy was required in almost 20% and had a success rate of over 90%.

## Surgery

may be warranted for select individuals who continue to complain of disabling coccygeal pain despite the implementation of various nonoperative treatment strategies.

In most instances, surgical management generally involves either excision of the mobile segment or a total coccygectomy.

These procedures are ideally reserved for patients with evidence of advanced degeneration such as coccygeal instability (e.g., subluxation or hypermobility) or spicule formation since this population appears to exhibit the greatest improvement postoperatively, with published success rates between 60 and 91%



- The most frequent complication of coccygectomy is wound infection, which has been shown to occur in up to 22% of these operative cases
- There is also a high incidence of cases where it just didn't work and the patient was either no better off after coccygectomy or maybe even worse.
- The only advice I offer in these cases is to choose the surgeon carefully and go for someone who has the most experience at this type of operation.

# Key Research Articles

Balain B, Eisenstein SM, Alo GO, et al. Coccygectomy for coccydynia: case series and review of literature. Spine. 2006;31:E414-E420.

[Abstract\(external link\)](#)

Fogel GR, Cunningham PY, Esses, SL. Coccygodynia: evaluation and management. J Am Acad Orthop Surg. 2004;12:49-54.

[Abstract\(external link\)](#)

Mlitz H, Jost W. Coccygodynia. J Dtsch Dermatol Ges. 2007;5:252-254.

[Abstract\(external link\)](#)

Wray CC, Easom S, Hoskinson J. Coccydynia. Aetiology and treatment. J Bone Joint Surg (Br). 1991;73-B:335-338.

[Full Text\(external link\)](#) [Abstract\(external link\)](#)

Hodges S, Eck JC, Humphreys SC. A treatment and outcomes analysis of patients with coccydynia. Spine J. 2004;4:138-140.

[Abstract\(external link\)](#)

Karadimas EJ, Trypsiannis G, Giannoudis PV. Surgical treatment of coccygodynia: an analytic review of the literature. Eur Spine J. 2011;20:698-705.

[Abstract\(external link\)](#)

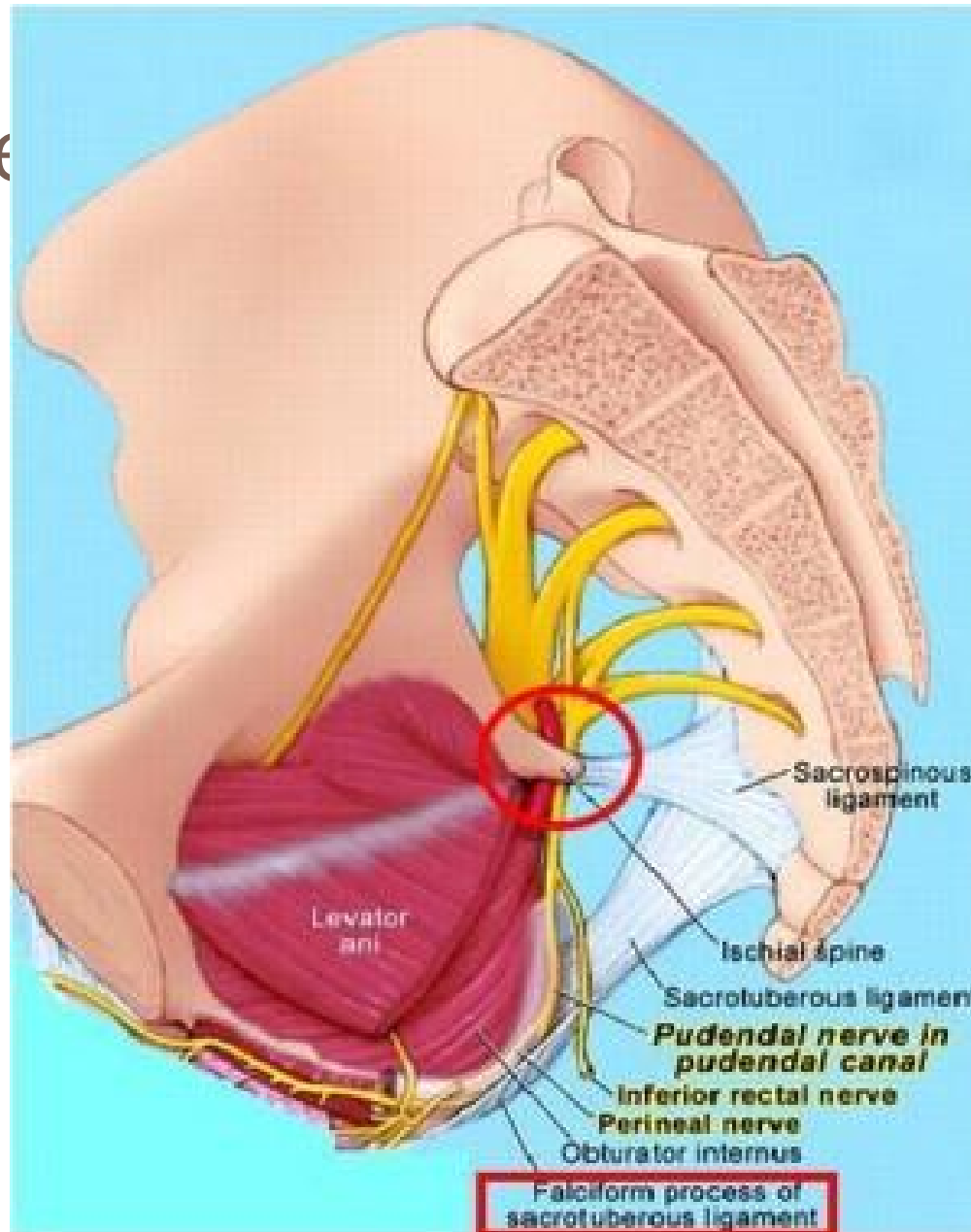
# Pudendal Nerve Entrapment

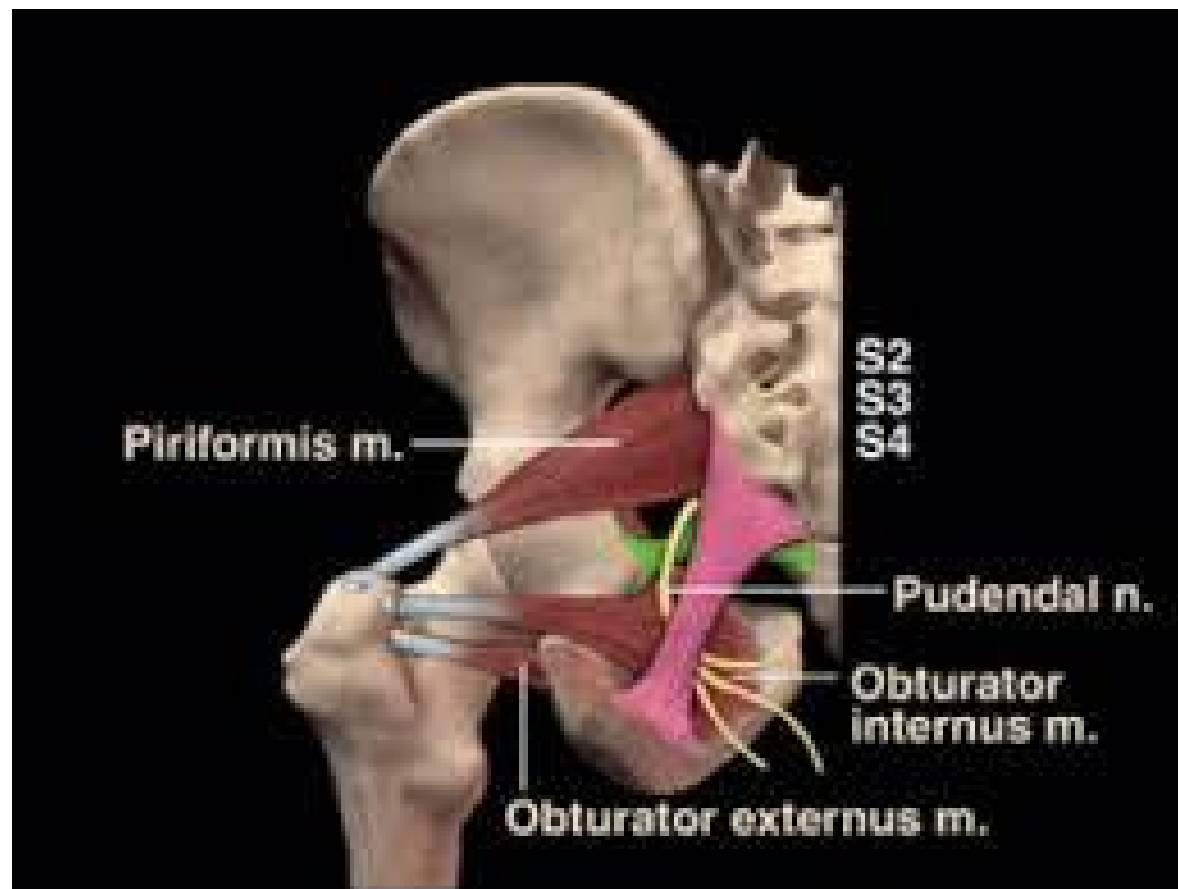
- **Pudendal nerve entrapment (PNE)**, also known as **Alcock canal syndrome**,<sup>[1][2]</sup> is an uncommon<sup>[1][3][4][5]</sup> source of chronic pain, in which the pudendal nerve (located in the pelvis) is entrapped or compressed.<sup>[6]</sup> Pain is positional and is worsened by sitting. Other symptoms include genital numbness, faecal incontinence and urinary incontinence.

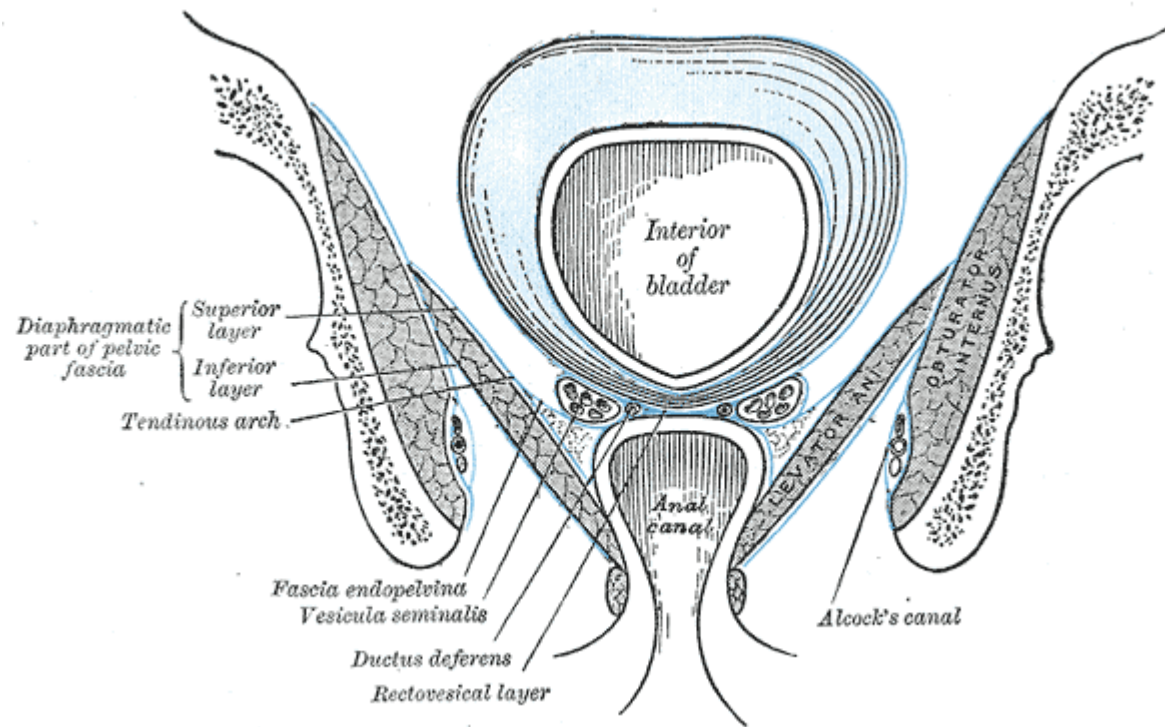
- Pudendal nerve neuropathy is likely to be a probable diagnosis if the pain is unilateral, has a burning quality and is exacerbated by unilateral rectal palpation of the ischial spine, with delayed pudendal motor latency on that side only.
- However, such cases account for only a small proportion of all those presenting with perineal pain. Proof of diagnosis rests on pain relief following decompression of the nerve in Alcock's canal and is rarely achieved.
- The value of the clinical neurophysiological investigations is debatable; some centres in Europe claim that the investigations have great sensitivity, while other centres, which also have a specialized interest in pelvic floor neurophysiology, have not identified any cases.
- — European Association of Urology, *Guidelines on Chronic Pelvic Pain*
-

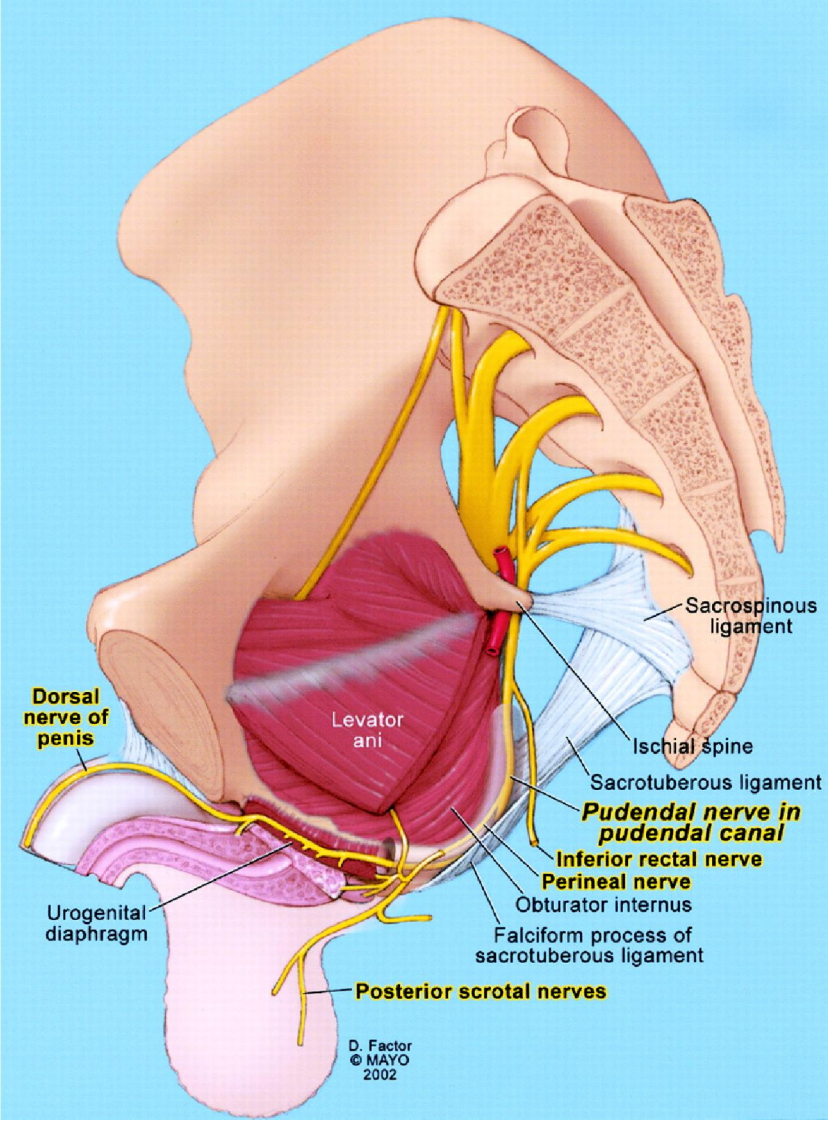
The

cks canal











# Cyclist Syndrome

- There are no specific clinical signs or complementary test results for this condition.<sup>[8]</sup>
- The typical symptoms of PNE or PN are seen, for example, in male competitive cyclists (it is often called "cyclist syndrome<sup>[5]</sup>), who can rarely develop recurrent numbness of the penis and scrotum after prolonged cycling, or an altered sensation of (urination) and reduced awareness of defecation.
- They even report strange sensations with ejaculation. <sup>9]</sup><sup>[10]</sup>
- Nerve entrapment syndromes, presenting as genitalia numbness, are amongst the most common bicycling associated urogenital problems.<sup>[11]</sup>

- The pain is typically caused by sitting, relieved by standing, and is absent when recumbent (lying down) or sitting on a toilet seat. <sup>[12]</sup>
- If the perineal pain is positional (changes with the patient's position, for example sitting or standing), this suggests a tunnel syndrome. <sup>[13]</sup>
- Other than positional pain and numbness, the main symptoms are faecal incontinence and urinary incontinence
- Differential diagnosis should consider the far commoner conditions chronic prostatitis in the male and interstitial cystitis in the female .

# Tests and imaging

- Similar to a Tinel sign at the wrist digital palpitation of the ischial spine may produce pain. In contrast, patients may report temporary relief with a diagnostic pudendal nerve block typically infiltrated near the ischial spine<sup>4</sup>[8]
- Electromyelography can be used to measure motor latency along the pudendal nerve. A greater than normal conduction delay can indicate entrapment of the nerve.<sup>[4]</sup>
- Imaging studies using MRI neurography may be useful. In patients with unilateral pudendal entrapment in the Alcocks canal it is typical to see asymmetric swelling and hyper intensity affecting the pudendal neurovascular bundle.<sup>[17]</sup>

# Causes

- PNE can be caused by pregnancy, scarring due to surgery (episiotomy) accidents and surgical mishaps. [\[18\]](#)
- Anatomic abnormalities can result in PNE due to the pudendal nerve being fused to different parts of the anatomy, or trapped between the sacrotuberous and sacrospinalis ligaments.
- Heavy and prolonged cycling especially if an inappropriately shaped or incorrectly positioned bicycle seat is used, may eventually thicken the sacrotuberous and/or sacrospinous ligaments and trap the nerve between them, resulting in PNE.

# Treatment

- 1. Pharmacology including Gabapentin
- 2. Physical therapy including osteopathy
  - SIJ and pelvic ring
  - Pelvic floor externally
  - Pelvic floor internally PR
  - FT along the canal
  - Direct inhibition techniques
- 3. Surgery to reduce the scars

- **Contact Details**

Dr Stephen Sandler PhD DO

sandlerosteo@gmail.com

07659 59 3509 pager

0208 529 0815

Chingford Practice

64 Station Rd Chingford E4 7BA

Portland Hospital Practice

The 3<sup>rd</sup> Floor

The Portland Hospital

212-214 Great Portland Street

London W1N