

ESCRS Guidelines for Prevention and Treatment of Endophthalmitis Following Cataract Surgery:

Data, Dilemmas and Conclusions
2013

Peter Barry

Luis Cordovés

Susanne Gardner



Endophthalmitis
Prevention & Treatment

ESCRS Guidelines for Prevention and Treatment of Endophthalmitis Following Cataract Surgery: Data, Dilemmas and Conclusions

Peter Barry FRCS, FRCOphth, FRCSI,
Consultant Ophthalmic Surgeon
Royal Victoria Eye and Ear and
St Vincent's University Hospital
Dublin, Ireland

Luis Cordovés MD
Retina and Vitreous Section
Ophthalmology Service
Hospital Universitario de Canarias, Spain

Susanne Gardner D. Pharm.
Specialist in Ocular Pharmacology
and Pharmacokinetics
Atlanta, Georgia, USA

These guidelines are dedicated to Per Montan and colleagues at St Erik's Eye Hospital, Stockholm, Sweden.
They are the unsung heroes of intracameral antibiotic prophylaxis of endophthalmitis following cataract surgery.

TABLE OF CONTENTS

1.	INTRODUCTION	1
2.	DEFINITION OF ENDOPHTHALMITIS	1
3.	PATHOPHYSIOLOGY OF POSTOPERATIVE ENDOPHTHALMITIS	2
4.	MICROBIAL SPECTRUM OF POSTOPERATIVE ENDOPHTHALMITIS	2
	Common sources of infection in postoperative endophthalmitis	2
	Commonly isolated microbial species in postoperative endophthalmitis	3
	Microbial spectrum of endophthalmitis in the ESCRS study	3
	Microbial spectrum of endophthalmitis: recent reports	4
	Methicillin-resistant <i>S. aureus</i> (MRSA) and <i>S. epidermidis</i> (MRSE), and increasing resistance to common topical antibiotics	5
5.	INCIDENCE OF ENDOPHTHALMITIS AFTER CATARACT SURGERY	7
	Historical background endophthalmitis rates	8
	Reduced endophthalmitis rates after initiation of intracameral antibiotic prophylaxis	8
6.	THE ENDOPHTHALMITIS VITRECTOMY STUDY (EVS)	10
7.	ESCRS STUDY ON PROPHYLAXIS OF ENDOPHTHALMITIS AFTER CATARACT SURGERY	10
8.	UPTAKE OF INTRACAMERAL CEFUROXIME AS PROPHYLAXIS OF POSTOPERATIVE ENDOPHTHALMITIS	13
9.	RISK FACTORS FOR POSTOPERATIVE ENDOPHTHALMITIS IDENTIFIED IN THE ESCRS STUDY	15
10.	PREOPERATIVE ANTISEPSIS	16
11.	OPERATING THEATRE	17
12.	DIAGNOSIS AND TREATMENT OF ACUTE AND CHRONIC ENDOPHTHALMITIS	18
	Diagnosis	18
	Microbiology testing	19
	PCR	20
	TASS vs Infectious endophthalmitis	20
	Treatment of acute postoperative endophthalmitis	21
	Chronic saccular endophthalmitis	24
13.	INTRAVITREAL ANTIBIOTICS	26
14.	ADJUNCTIVE SYSTEMIC ANTIBIOTIC TREATMENT	27
15.	DILEMMAS IN THE PREVENTION OF POSTOPERATIVE ENDOPHTHALMITIS	28
	Allergy to cefuroxime	28
	Choice of postoperative drop regimen	29
	Choice of intracameral injection, subconjunctival injection or topical drops	30
	APPENDIX I PREPARATION OF INTRAVITREAL DOSES	31
	APPENDIX II PHARMACOKINETICS and PHARMACODYNAMICS (PK/PD): fundamentals for understanding antibiotic action in the eye	33
	REFERENCES AND BIBLIOGRAPHY	39

1 INTRODUCTION

Endophthalmitis is a serious complication of cataract surgery that every ophthalmic surgeon - and patient - strives to avoid. The visual loss and debilitation that occur in a large proportion of postoperative endophthalmitis cases can be severe and irreversible. Those most in need of the operation are often those at greatest risk, such as the elderly. Without knowing exactly how, when or why to intervene with effective prophylactic measures, virtually every surgeon today follows a standard of care that involves antisepsis and antibiotics.

Although cataract surgery ranks among the most frequently performed surgical procedures worldwide, data to define the most effective prophylactic measures have been nearly impossible to generate, given the large patient numbers needed to conduct clinical trials. Prevention and elimination of postoperative endophthalmitis, however, is a constant goal of every ophthalmic surgeon.

The clinical practice of administering a direct intracameral injection of cefuroxime at the close of cataract surgery to reduce endophthalmitis rates was first implemented by a group of Swedish surgeons, to whom this edition of the Guidelines is dedicated. The clinical benefit of this intervention seemed apparent. In order to test the hypothesis in a scientific manner, the European Society of Cataract and Refractive Surgeons mounted a large randomized clinical trial to evaluate the intracameral

injection in a prospective, randomized fashion across nine European countries. Results published in 2007 unequivocally demonstrated a clinical benefit, with a five-fold reduction in postoperative endophthalmitis rates in patients who received a 1mg intracameral injection of cefuroxime at the close of cataract surgery¹.

In the wake of these results, a growing number of centres have adopted this method of prophylaxis, reporting even more striking effects, on occasion, than the ESCRS study itself. In parallel, scientific principles that underlie microbial eradication in the atypical spaces of the eye have been explored. These data and scientific principles are presented in an evidence-based manner in this publication of the ESCRS Guidelines for Prevention and Treatment of Endophthalmitis following cataract surgery.

Sections 1 through 15 review etiology, microbiology and recent study reports, and present guidelines for prevention, diagnosis and treatment of postoperative endophthalmitis. Appendix I presents instructions for preparing intravitreal injections and Appendix II provides an overview of pharmacokinetics/pharmacodynamics, the scientific principles that help us understand how bacteria may be eradicated in the atypical spaces of the eye. These fundamental principles support the rationale of the intracameral injection and help to navigate the literature on this essential topic.

2 DEFINITION OF ENDOPHTHALMITIS

Postoperative endophthalmitis is an inflammatory condition of the eye, presumed to be due to an infectious process from bacteria, fungi or, on rare occasions, parasites that enter the eye during the perioperative period. Other forms of endophthalmitis may arise from endogenous sources where septicaemia spreads to the internal eye, or from perforating injury to the eye from objects or organic matter, but these conditions involve clinical presentations and management guidelines substantially different from endophthalmitis after cataract surgery. Endophthalmitis following bleb procedures for the treatment of glaucoma

also comprises a spectrum of bacteria and management guidelines that differ from postoperative endophthalmitis after cataract surgery.

Exogenous endophthalmitis may present in an acute, virulent form, or a more chronic, late endophthalmitis. In these Guidelines, we focus on the prophylaxis and management of the exogenous form of endophthalmitis that occurs after cataract surgery, and where bacterial infection stems from contamination of the wound and internal eye in the perioperative environment.

3 PATHOPHYSIOLOGY OF POSTOPERATIVE ENDOPHTHALMITIS

The severity and clinical course of postoperative endophthalmitis is related to the virulence and inoculum of infecting bacteria, as well as time to diagnosis and the patient's immune status.

The infectious process undergoes an initial incubation phase which may be clinically unapparent, lasting at least 16-18 hours, during which a critical load of bacteria proliferate and break down the aqueous barrier; this is followed by fibrin exudation and cellular infiltration by neutrophilic granulocytes. The incubation phase varies with the generation time of the infecting microbe, (eg: up to 10 minutes for *S. aureus* and *Ps. aeruginosa*; over 5 hours for *Propionibacterium* spp.) along with other factors such as production of bacterial toxins. With common microorganisms such as *S. epidermidis* (CNS) as much as

3 days may lapse before the infiltration reaches its peak. An acceleration phase and, finally, a destructive phase of the infection develops.

The acceleration phase follows primary infection of the posterior segment and leads to inflammation of the anterior chamber and an immune response with macrophages and lymphocytes infiltrating into the vitreous cavity within about 7 days. By 3 days after intraocular infection, pathogen-specific antibodies can be detected; these help to eliminate microbes through opsonisation and phagocytosis within about 10 days. Consequently, laboratory results may prove negative while severe inflammation is occurring within the eye. Inflammatory mediators, especially cytokines, further recruit leucocytes, which may add to destructive effects, retinal injury and vitreoretinal proliferation.

4 MICROBIAL SPECTRUM OF POSTOPERATIVE ENDOPHTHALMITIS

The infecting microorganisms in postoperative endophthalmitis originate from environmental, climatic, surgical, and patient-specific factors, among others. In these Guidelines, we focus on prophylaxis of endophthalmitis after cataract surgery, and the microorganisms most commonly implicated in these intraocular infections.

COMMON SOURCES OF INFECTION IN POSTOPERATIVE ENDOPHTHALMITIS

The etiology of microorganisms infecting the eye during cataract surgery include the following:

- the patient's own ocular surface flora [Speaker 1991, Bannerman 1997]. A majority of contaminants during, and even after, surgery can be traced to the patient's own ocular surface flora. The self-administration of topical antibiotic drops in the early postoperative period and the patient's personal habits also play a role during this critical period of wound healing.
- infection stemming from contaminated surgical instruments, tubing or the surgical environment, where occasional clusters of infection suggest a local epidemic [Pathengay 2012]. Measures needed to assure the sterility of the surgical suite, airflow and instruments are briefly outlined here, but are too broad for comprehensive review, and the reader is referred to appropriate guidelines and practice standards.

- surgical complications. Surgical complications are a known risk factor for endophthalmitis, with higher endophthalmitis rates cited where complications occur. Although the internal eye is protected to some degree by ocular barriers that confer an "immune privilege," if compromised (e.g. by an intra-operative capsular defect with vitreous loss) the risk of endophthalmitis may increase by as much as 10-fold or more.
- poor or delayed wound healing. Delayed wound healing increases the risk for infection. An influx of ocular surface tears may occur postoperatively, allowing access of surface flora to the internal eye.
- patients presenting preoperatively with blepharitis and inflammation or infection of the eyelids. It is worthwhile mentioning that atopic patients and those with rosacea have altered conjunctival and lid bacterial flora, with a higher preponderance of *Staphylococcus aureus*. Patients with rosacea also exhibit an enhanced systemic cell-mediated immunity to *S. aureus*, which may contribute to the observed blepharitis and keratitis [Miño de Kaspar 2003, Seal 1995]. These patients should undergo treatment for their blepharitis prior to cataract surgery with appropriate antibiotic therapy.

COMMONLY ISOLATED MICROBIAL SPECIES IN POSTOPERATIVE ENDOPTHALMITIS

The majority of bacteria causing endophthalmitis after cataract surgery in Western countries are Gram-positive microbes, described with varying frequency in reported series. Visual outcome may be especially poor with infection by virulent strains of streptococci that exude exotoxins, and by Gram-negative microbes such as *Pseudomonas aeruginosa*, although the latter occurs less frequently in Western countries.

The severity of intraocular infection is related to inoculum size and virulence of the bacteria, host immune responses, the perioperative measures taken and the time to presentation of infection. Because none of these factors can be precisely quantified or identified prior to cataract surgery, prophylactic measures must rely on evidence-

based data to derive logical approaches to the eradication of bacteria and prevention of infection.

Tables 1 and 2 display bacteria most commonly identified in endophthalmitis after cataract surgery in many Western countries; these may include CNS (*S. epidermidis*), *S. aureus* (including MRSA), β -hemolytic streptococci, *E. faecalis* among Gram-positive organisms; Gram-negative rods including *Haemophilus influenzae* and *Ps. aeruginosa* among Gram-negative microorganisms. The spectrum varies in cases of chronic endophthalmitis, with *P. acnes*, Diphtheroids, CNS (*S. epidermidis*) and fungi more commonly isolated (Table 2). (Most fungal exogenous post-cataract endophthalmitis are due to filamentous fungi, particularly *Aspergillus* spp). The etiology of postoperative endophthalmitis may vary with regions of the world, as depicted in Table 6.

Table 1. Common microorganisms in postoperative endophthalmitis

Prevalence (%)*	Bacterial species
33 - 77%	CNS (coagulase-negative staphylococci)
10 - 21%	<i>Staphylococcus aureus</i>
9 - 19%	BHS (β -haemolytic streptococci), <i>S. pneumoniae</i> , β -haemolytic streptococci including <i>S. mitis</i> and <i>S. salivarius</i>
6 - 22%	Gram-negative bacteria including <i>Ps. aeruginosa</i>
up to 8%	Fungi (<i>Candida</i> sp., <i>Aspergillus</i> sp., <i>Fusarium</i> sp.)

* Commonly cited prevalence may vary with geographic regions

Table 2. Common microorganisms in chronic or delayed (saccular) postoperative endophthalmitis

<i>Propionibacterium acnes</i>
<i>Corynebacterium</i> spp
<i>S. epidermidis</i>
fungi

MICROBIAL SPECTRUM OF ENDOPTHALMITIS IN THE ESCRS STUDY

The microorganisms identified in the four ESCRS study groups appear in Table 3. In keeping with most reports, Gram-positive microbes predominated, including species of coagulase-negative staphylococci (CNS), streptococci, and also other staphylococci. Particularly in Group A, the group *without* intracameral cefuroxime (that received only standard preoperative povidone-iodine, and postoperative

levofloxacin drops beginning the day after surgery), a relatively high incidence of *Streptococcus* spp. is seen. These strains are often virulent, producing exotoxins, and are associated with poor visual outcome; they represent an important group of pathogens to be considered when selecting a prophylactic antibiotic regimen. (No Gram-negative organisms were identified in ESCRS cases of endophthalmitis).

Table 3. Bacterial isolates in ESCRS study groups¹

<p>Group A Placebo vehicle drops x 5* No intracameral injection</p> <p>2 <i>Streptococcus pneumoniae</i> 1 <i>Streptococcus salivarius</i> 1 <i>Streptococcus suis</i> 1 <i>Streptococcus mitis</i>, <i>Staphylococcus epidermidis</i> 1 <i>Staphylococcus aureus</i>, <i>Staphylococcus epidermidis</i>, <i>Propionibacterium acnes</i> 3 <i>Staphylococcus epidermidis</i>[†] 1 <i>Propionibacterium acnes</i> †One removed for PP analysis</p>	<p>Group B Placebo vehicle drops x 5* Intracameral cefuroxime injection</p> <p>2 <i>Staphylococcus epidermidis</i></p>
<p>Group C Levofloxacin drops 0.5% x 5* No intracameral injection</p> <p>1 <i>Streptococcus salivarius</i> 1 <i>Streptococcus sanguinis</i> 1 <i>Streptococcus oralis</i> 1 <i>Staphylococcus aureus</i> 2 <i>Staphylococcus epidermidis</i> 1 <i>Staphylococcus hominis/haemolyticus</i></p>	<p>Group D Levofloxacin drops 0.5% x 5* Intracameral cefuroxime injection</p> <p>1 <i>Staphylococcus warneri</i></p>

* One drop 1 hour before surgery, 1 drop half an hour before surgery, 1 drop immediately postoperation, 1 drop 5 minutes later, and 1 drop 5 minutes later again. All groups received povidone-iodine 5% (Betadine) before surgery and were presented levofloxacin 0.5% eyedrops from days 1 to 6 after surgery 4 times daily.

MICROBIAL SPECTRUM OF ENDOPTHALMITIS: RECENT REPORTS

The microorganisms most commonly identified in postoperative endophthalmitis may vary with regions of the world, as further discussed below. However, a recent report from Northern California² offers an interesting comparison with the ESCRS study that was conducted in Europe, in terms of bacterial etiology and other results as well. Table 4 shows that *Staphylococcus* spp. and *Streptococcus* spp. predominated with comparable incidence rates in both studies.

In Sweden, where intracameral cefuroxime has been used extensively, the Swedish Cataract Register routinely tracks the spectrum of microorganisms isolated in cases of postoperative endophthalmitis. The recent report by Friling and associates³ presents six-year results, shown in Table 5.

Here, routine use of intracameral cefuroxime may have led to a shift in the preponderance of isolated species in endophthalmitis cases, as reported in the large Swedish series. A shift in preponderance may alter clinical presentation and require adjustments in management. Careful analysis of this data shows that the absolute incidence of enterococcal infections has likely not increased over the years, but only increased in proportion to the relatively reduced rates of infection now seen from CNS and other more common organisms.

Table 4. Comparison of microorganisms isolated in ESCRS, Shorstein studies

	ESCRS ¹	SHORSTEIN et al. ²
<i>Staphylococcus</i>		
I/C Antibiotic	3/8000	0/3653
No I/C Antibiotic	8/8000	5/3653
<i>Streptococcus</i>		
I/C Antibiotic	0/8000	0/3653
No I/C Antibiotic	8/8000	3/3653

Table 5. Microorganisms identified in endophthalmitis isolates, Swedish National Study

Species	(n)	(%)
Enterococci	42	31%
CNS	35	26%
Other streptococci	9	7%
Other gram-positive	8	6%
<i>Pseudomonas</i> species	10	7%
Enterobacteria species	7	5%
Other gram-negative	2	1%
Culture +, no species report	2	1%
No growth	17	13%
Culture not taken	3	2%
Total	135	100%

Adapted from Friling et al. 2013

MICROBIAL SPECTRUM OF ENDOPTHALMITIS IN VARIOUS REGIONS

The microbiologic spectrum of post-cataract endophthalmitis has wide geographical variations as seen in the series depicted in Table 6. In countries such as India and China, the percentage of Gram-negative and fungal

cases can be much higher [Anand 2000] than in Europe and the USA, whereas a higher rate of streptococcal infections are reported in Europe compared with the USA. (The lower rate of streptococcal infections seen in the EVS could be due to the fact that many of the most severe cases were excluded; further discussion below.)

Table 6. Etiology (%) of postoperative endophthalmitis in various regions

MICROBES	EVS ¹	UK ²	NETHERLANDS ³	INDIA ⁴	INDIA ⁵	CHINA ⁶
GRAM-POSITIVE		93.4			53.1	73.9
CNS	70	62.3	53.6	18.6	33.3	45.5
S. AUREUS	10	4.9	12	11.4		12.4
STREPTOCOCCUS SPP.	9	19.6	19	2.9	10.3	6.2
ENTEROCOCCUS SPP.	2	3.3	1.8	1.4		7.2
OTHER GRAM-POSITIVE	3	3.3	5.2	10		2.6
GRAM-NEGATIVE	6	6.6	6	42	26.2	13.4
FUNGAL	-	-	-	7.1	16.7	12.7

Note that polymicrobial cultures occurred and are not separately identified.

1 Adapted from Han et al. 1996.

2 Adapted from, Mollan et al. 2007.

3 Adapted from Pijl et al. 2010.

4 Adapted from Jambulingam et al. 2010.

5 Adapted from Kunimoto et al. 1999. "Gram-positive" includes 46.8% cocci and 6.3% bacilli.

CNS specified as *S. epidermidis*. *Ps. aeruginosa* accounted for 19.8% of "Gram-negative" microbes.

6 Adapted from Sheng et al. 2011.

METHICILLIN-RESISTANT *S. AUREUS* (MRSA) AND *S. EPIDERMIDIS* (MRSE), AND INCREASING RESISTANCE TO COMMON TOPICAL ANTIBIOTICS

The issue of potential infection by MRSA and MRSE is gaining attention as more of these resistant strains appear in endophthalmitis isolates from around the world. In 2010, Major and associates from the Bascom Palmer Eye Institute, USA, reported that MRSA was recovered in 41% of 32 cases of endophthalmitis caused by *Staphylococcus aureus* (after various ocular surgeries) in a retrospective series dated January 1, 1995 through January 1, 2008. Of interest, MRSA isolates showed a 62% resistance rate to the fourth generation fluoroquinolones moxifloxacin and gatifloxacin [per Fig. 1, Major et al, AJO 2010]. In this series, as in the Ocular TRUST report, MRSA were highly susceptible to trimethoprim, but poorly susceptible to fluoroquinolones and other agents. In Ocular TRUST, only 15.2% of MRSA isolates were susceptible to the fluoroquinolones tested.

The reported incidence of MRSA/E in ocular infections varies with regions of the world and a number of recent reports from Asia find relatively high proportions in conjunctival samples. The reader is encouraged to be alert to local bacterial susceptibility/resistance trends. The map below identifies the proportion of methicillin-resistant *Staphylococcus aureus* isolates identified in participating countries within Europe. (Note that depicted resistance rates may have varied, or been higher, during the ESCRS study period, as related to implemented infection control measures).

However, no MRSA cases of endophthalmitis occurred in the ESCRS study; (patients at high risk, such as those in nursing homes, were excluded from the study)⁴. It is worthwhile noting that all isolates of streptococci were resistant to gentamicin, consistent with the poor activity of this agent against *Streptococcus* spp. In the study by Shorstein and associates² only one case of MRSA was identified, occurring in 2008 in a patient that had not received intracameral antibiotic but did receive postoperative tobramycin drops.

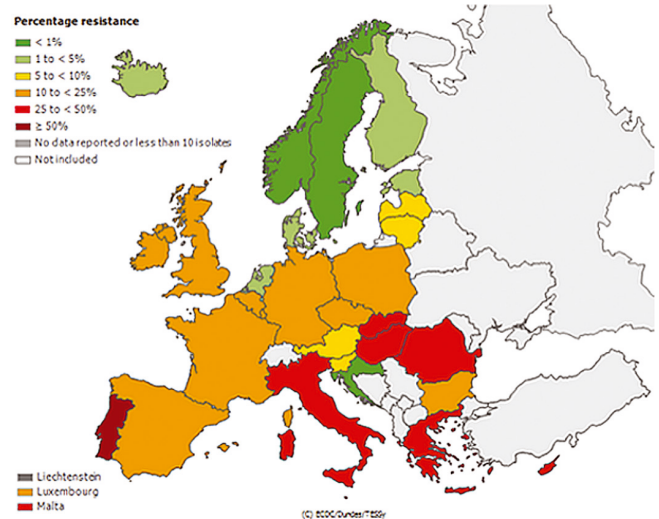
In the ESCRS study, 3 strains of *S. epidermidis* were isolated that were considered resistant to oxacillin (resistance defined with MICs of 0.75 and 1 mcg/ml). Two of these strains were also classified as resistant to cefuroxime (with MICs of 1.5 and 3 mcg/ml; however, BSAC and DIN breakpoints were ≤ 4 mcg/ml, CLSI breakpoint was ≤ 8 mcg/ml).

These reports emphasize the need for local susceptibility testing, and an understanding of pharmacokinetic/pharmacodynamic principles underlying bacterial eradication, as described in Appendix II of these Guidelines. Measures in Europe to contain MRSA infection may include screening for patients at risk, such as inpatients and those in long term care, although most outpatients do not routinely undergo screening for MRSA.

The current drug of choice for treatment of MRSA/MRSE infection is vancomycin, but its prophylactic use is discouraged; vancomycin should be reserved for treatment. However, where a patient is known to carry MRSA and requires cataract surgery, intracameral vancomycin is used in some centres and seems justified in this circumstance. While neither cefuroxime nor fluoroquinolones are indicated for treatment of MRSA/E, there is a possibility that very high applied concentrations may exert an effect against strains not classified as susceptible by standard laboratory definitions, although no such guidance exists. (See Appendix II for insight into time/kill profiles for bacterial eradication.) Preoperative ocular surface antisepsis

with PVI (or chlorhexidine), as discussed below, is an essential element of prophylaxis. Povidone-iodine does exhibit activity against MRSA/E although reported time/concentration/kill curves vary.

Figure 1.



Proportion of Methicillin Resistant *S. aureus* (MRSA) isolates in Europe in 2011
Reproduced from ECDC database

5 INCIDENCE OF ENDOPHTHALMITIS AFTER CATARACT SURGERY

Modern day endophthalmitis rates have dropped considerably in countries where the intracameral injection was adopted as a routine method of prophylaxis after cataract surgery. The majority of centres utilized intracameral cefuroxime following published results of the ESCRS study in 2007 and initial reports from Sweden.

Table 7 shows the striking drop in recent years of reported postoperative endophthalmitis from rates near 0.3% - 1.2% prior to the institution of intracameral cefuroxime, to

rates of only 0.014 - 0.08% after institution of intracameral cefuroxime at the close of surgery - a reduction of approximately 7 to 28 fold, overall, in postoperative endophthalmitis rates.

Results from three series where intracameral cefazolin was injected at the close of cataract surgery are also shown in Table 8.

Table 7. Reported incidence (% , number of patients) of postoperative endophthalmitis with/without use of intracameral (IC) cefuroxime

WITH IC CEFUROXIME	WITHOUT IC CEFUROXIME	COUNTRY	REFERENCE (number of patients)
0.048	0.35 ^a	Sweden	Lundstrom, ⁵ 2007 - (225,000)
0.05	0.35	9 countries ^b	ESCRS study, ¹ 2007 - (16,000)
0.044 (2289) ^c	1.238 (2826) ^c	France	Barreau, ⁶ 2012 - (5115 total) ^c
0.08 (3971) ^d	0.55 (4219) ^d	South Africa	Van der Merwe, ⁷ 2012 (8190 total) ^d
0.014 ^e	0.31 ^f	United States	Shorstein, ² 2013 (16,264) ^{e,f}
0.043 (7057) ^g	0.59 (6595) ^g	Spain	Garcia-Saenz, ⁸ 2010 - (13,652 total) ^g
0.039 (12 868) ^h	0.59 (6595) ^h	Spain	Rodríguez-Caravaca, ⁹ 2013 (19,463) ^h
0.027 (455 054) ⁱ	0.39 ⁱ	Sweden	Friling, ³ 2013 (464,996)

a. In sub-group of 11,000 patients without intracameral cefuroxime.
b. Countries included Austria, Belgium, Germany, Italy, Poland, Portugal, Spain, Turkey, United Kingdom.
c. Post-IC cefuroxime use, 2006-2008 in 2289 patients; pre-IC cefuroxime use, 2003-2006, in 2826 patients.
d. Post-IC cefuroxime use, 2006-2009, in 3971 patients; pre-IC cefuroxime use, 2003-2006, in 4219 patients.
e. Rates for period when IC cefuroxime used in all patients unless suspected allergy when IC moxifloxacin or IC vancomycin was substituted.
f. Rates prior to IC cefuroxime use.
g. Post-IC cefuroxime use, 2005-2008, in 7057 patients; pre-IC cefuroxime use, 1999-2005, in 6595 patients.
h. Rates for 1999-October 2005, prior to IC cefuroxime and for October 2005-2012, after initiating IC cefuroxime. This series expands patient base of Garcia Saenz 2010.
i. Cefuroxime 1mg used in 455 054 cases (0.026%); moxifloxacin 0.2mg used in 6897 cases (0.029%); approximately 4% of cases combined cefuroxime 1mg and ampicillin 100 µg.

Table 8. Reported incidence (% , number of patients) of postoperative endophthalmitis with/without use of intracameral cefazolin

WITH IC CEFAZOLIN	WITHOUT IC CEFAZOLIN	COUNTRY	REFERENCE (number of patients)
0.01 (20 638) ^a	0.064 (29 539) ^a	Singapore	Tan, 2012 (50 177)
0.05 (13 305) ^b	0.63 (11 696) ^b	Spain	Romero-Aroca, 2012 (25 001)
0.047 (12 649) ^c	0.422 (5930) ^c	Spain	Garat 2009 (18 579)

a. From July 1999-June 2006, subconjunctival cefazolin and other agents were given at end of surgery. From July 2006 to June 30, 2010, cefazolin was changed to intracameral injection.
b. From January 1996-December 2002, no intracameral cefazolin was administered. From January 2003-December 2009, patients received intracameral cefazolin 1mg cefazolin at the end of surgery.
c. From January 2002 - December 2003, no intracameral cefazolin was administered. From January 2004-December 2007, patients received intracameral cefazolin 2.5mg at the end of surgery.

HISTORICAL BACKGROUND ENDOPHTHALMITIS RATES

Reported background postoperative endophthalmitis rates have fluctuated over the past 50 years, along with advances in surgical techniques, such as ICCE without suture, to ICCE with suture, ECCE with IOL and sutures, phacoemulsification, initially with incision enlargement to accommodate rigid IOL, then phacoemulsification with small incision IOL, among other factors. Utilisation of, and improvements in, surgical microscopes also contributed substantially to the overall quality of the surgical procedure.

Early in the 20th century, the incidence of endophthalmitis after cataract surgery was fairly high - approximately 10%. The advent of ECCE (extracapsular cataract extraction) using a scleral or limbal incision, along with improved hygiene, reduced this infection rate (c. 1970-1990) to approximately 0.12% in Europe and 0.072% in the United States. For the decade between 1990 - 2000, reported endophthalmitis rates varied greatly, actually increasing after the introduction of phacoemulsification and clear cornea incisions (CCI), with some retrospective studies reporting rates between 0.3 - 0.5%.

A degree of controversy has arisen in recent years over endophthalmitis rates in U.S. surgical centres that claimed rates already as low as those achieved in European countries that use an intracameral injection, presumably because of their more aggressive use of perioperative antibiotic drops in lieu of intracameral injection. These

reports, however, reflected individual series or centres, were retrospective and were not population based. An analysis of postoperative endophthalmitis derived from the U.S. Medicare database of 2003-4, showed that endophthalmitis rates could vary substantially among individual states and with frequency of surgeries per surgeon. [Keay 2012]

In the recent U.S. report² the “background” rate in that Northern California region, prior to implementation of intracameral antibiotics, was very similar to the rate in the ESCRS study control Group A (near 0.35%), suggesting this number may be nearer a true “background” rate. These two studies are also consistent with the Swedish report⁵, where background rates of postoperative endophthalmitis were very similar (0.31%, Shorstein; 0.35%, ESCRS study Group A; 0.35%, Lundstrom subgroup without IC cefuroxime). Tables 7 and 8 display the higher background endophthalmitis rates, all above 0.3%, that prevailed *prior* to implementation of an intracameral injection after cataract surgery.

Findings now point to the reality that endophthalmitis rates do vary among regions of the world, surgical centres and populations. Furthermore, each surgeon faces the possibility that specific risk factors may impact any one patient and increase the risk of infection.

Beyond Europe and North America, the need to address postoperative endophthalmitis may be even more compelling, as infection rates in developing countries are often higher, and infecting microbes more difficult to treat.

REDUCED ENDOPHTHALMITIS RATES AFTER INITIATION OF INTRACAMERAL ANTIBIOTIC PROPHYLAXIS

More important, is the now universal finding that when prophylaxis with intracameral injection of 1 mg cefuroxime at the close of cataract surgery is initiated, a clinical benefit ensues in the reduction of postoperative endophthalmitis rates by several-fold. Tables 7 and 8 display the dramatic reduction in infection rates after intracameral antibiotics became a standard prophylactic intervention.

The recent report by Rodríguez-Caravaca and associates⁹ from Spain, which expands on the 2010 report by Garcia-Saenz, shows that endophthalmitis rates dropped from 0.59% to 0.039% (5/12 868 cases), after addition of intracameral cefuroxime (Table 7). In 6595 cases during the period 1999 - October 2005, the endophthalmitis rate was 0.59% (39/6595 cases), where the prophylactic regimen included PVI (or chlorhexidine), postoperative ofloxacin 0.3% and dexamethasone 0.1% drops, and gentamicin 20mg subconjunctivally in cases of retrobulbar anesthesia. During the period October 2005 to December 2012, intracameral cefuroxime 1mg (or vancomycin in allergic patients) was added to the regimen, with a subsequent drop in endophthalmitis rates of approximately 15-fold.

The 2013 update from the Swedish National Cataract Register³ reports an incidence of 0.029% in 464 996 cataract operations over a six-year period, and also shows that addition of topical antibiotic drop prophylaxis did not confer a clear clinical benefit over the intracameral antibiotic intervention.

Report by Shorstein and Associates (United States) 2013

A recent and interesting report from the United States² presents data from a Northern California centre that allows comparison with ESCRS study results in Europe.

The U.S. study examined endophthalmitis rates for three time periods that reflected a gradual increase in the use of IC cefuroxime (Table 9): prior to September 2007, no intracameral injection; September 2007- December 2009, 1 mg cefuroxime given except in cases of posterior capsule rupture or suspected allergy to penicillin/cephalosporin; January 2010-December 2011, intracameral antibiotic administered in all eyes including those with posterior capsule rupture and suspected penicillin/cephalosporin allergy (moxifloxacin or vancomycin was used in those cases of allergy).

Table 9. Decreasing endophthalmitis rates with increasing use of intracameral antibiotics

Decreased postoperative Endophthalmitis rate after institution of intracameral antibiotics in a Northern California Eye Department		
Endophthalmitis Rates		
2007	Pre I/C Cefuroxime	0.31%
2007-2009	Excluding allergy/PCR	0.143% 2.2x
2010-2011	All patients	0.014% 10.2x

Adapted from reference²

The overall reduction in endophthalmitis rates - from the pre-IC injection period, to the time when all patients received the IC injections - was from 0.31% to 0.014%, an overall 22-fold reduction! (This report also underscores the efficacy of intracameral cefuroxime in cases of posterior capsular rupture.) These findings lend tremendous support to findings of the ESCRS study regarding the intracameral injection, particularly since the use of topical antibiotic drops was not restricted in that U.S. study.

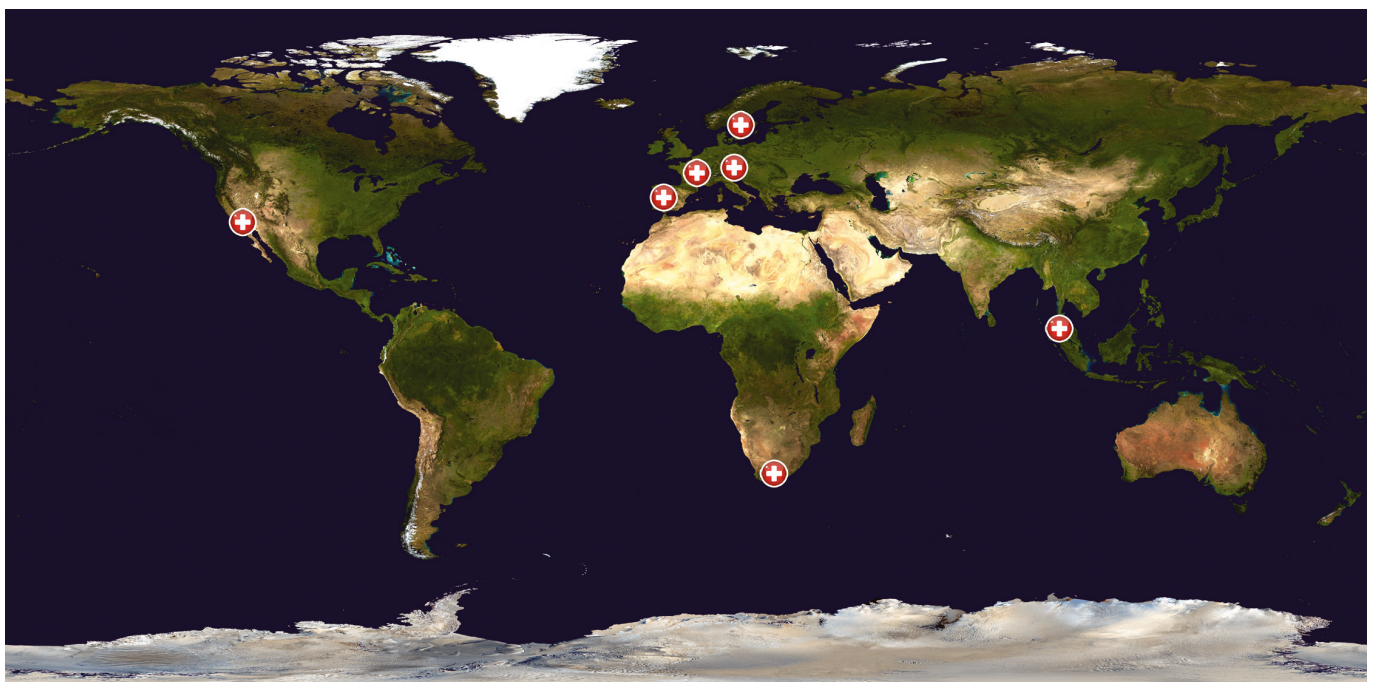
A recent study from Singapore also lends support to the intracameral injection where cefazolin was used, rather than cefuroxime. Tan and associates (2012) (Table 8) evaluated

postoperative endophthalmitis rates prior to, and after, the initiation of intracameral cefazolin at the close of surgery. Prophylaxis in prior time periods included subconjunctival cefazolin, gentamicin, dexamethasone; subconjunctival cefazolin was then changed to intracameral cefazolin injection, with other interventions remaining similar. Endophthalmitis rates prior to IC cefazolin were 0.064% (29 539 patients), but reduced to 0.01% (20 638 patients) when intracameral cefazolin was added to prophylactic regimens - a reduction in endophthalmitis rates of approximately 6-fold.

Romero-Aroca⁹ also describes results before and after an intracameral cefazolin injection was routinely administered at the close of cataract surgery. After initiation of the intracameral injection (pre-dating the ESCRS study), postoperative endophthalmitis rates were reduced approximately 12-fold (Table 8). Garat (2009) reported an almost 9-fold reduction in postoperative endophthalmitis rates when intracameral cefazolin was initiated after phacoemulsification procedures.

These most recent additions to the literature, originating worldwide (Figure 2) continue to support fundamental findings of the ESCRS study on prophylaxis of endophthalmitis and the clinical benefit of the intracameral cefuroxime injection.

Figure 2. Reported patient series utilizing intracameral antibiotic prophylaxis



6 THE ENDOPHTHALMITIS VITRECTOMY STUDY (EVS)

An important backdrop to the ESCRS study was the Endophthalmitis Vitrectomy Study¹⁰ (EVS) conducted in the United States from 1990-1995, led by Bernard Doft MD, with the support of the National Eye Institute (NEI). Its purpose was: to investigate the role of initial pars plana vitrectomy in the management of postoperative bacterial endophthalmitis; determine the role of intravenous antibiotics in management; and determine which factors, other than treatment, could predict outcomes in postoperative bacterial endophthalmitis.

The study randomly assigned patients, who developed acute endophthalmitis after cataract surgery, to intravitreal antibiotics and to one of 4 treatment groups, in a 2x2 factorial design, to evaluate the role of vitrectomy and intravenous antibiotics, as follows:

- 1) Vitrectomy + intravenous antibiotic
- 2) Vitrectomy, no intravenous antibiotics
- 3) Tap-biopsy + intravenous antibiotic
- 4) Tap-biopsy, no intravenous antibiotic

Vitrectomy: Results for visual acuity and media clarity at 9 months for vitrectomy were as follows:

- patients presenting with hand motion acuity or better showed no benefit from immediate vitrectomy, however,
- patients presenting with light-perception-only VA had substantial benefit from immediate vitrectomy, with:
 - a 3-fold greater frequency of achieving 20/40 vision or better

- twice the frequency of achieving 20/100 or better
- decrease by one-half in frequency of severe visual loss to < 5/200.

Intravenous antibiotic: There was no statistical difference in final visual acuity or media clarity between patients who received systemic antibiotics or not.

The study concluded that patients who presented with hand motion or better vision may be treated with tap or biopsy; patients presenting with light perception only vision should be considered for immediate PPV (pars plana vitrectomy); intravenous antibiotics were of no proven benefit. Results of the EVS study are presented here for historical perspective (but may not reflect current clinical practice).

The EVS excluded the most severe cases (those with no LP visual acuity at presentation, or media clarity considered insufficient to perform a safe vitrectomy). Of the 855 patients presenting with endophthalmitis within 6 weeks, 510 met eligibility criteria and finally 420 were enrolled. This may have shifted the results towards a more favorable outcome.

While these were findings from the EVS study, published in 1995, conclusions drawn from that study do not necessarily reflect current ESCRS Guidelines. More discussion on aspects of this study, and the potential role of systemically administered antibiotics are discussed below.

7 ESCRS STUDY ON PROPHYLAXIS OF ENDOPHTHALMITIS AFTER CATARACT SURGERY

The literature offers limited data for clinicians to make rational and informed decisions about the choice of prophylactic interventions for cataract surgery. Because huge numbers of patients are required to construct prospective, randomized clinical trials, few such trials are likely to be conducted. Only one study has undertaken this challenge and produced statistically significant results that clearly define the value of a single intervention - the intracameral injection.

The ESCRS study on prophylaxis of postoperative endophthalmitis following cataract surgery presented results in 2007 that described endophthalmitis rates among four study groups evaluating the effects of four perioperative prophylactic regimens¹. The study was designed primarily to answer one fundamental question - do perioperative antibiotics prevent endophthalmitis, and if so, then how should they be administered (ie: intracameral, topical)? The study also helped to establish a background

rate of postoperative endophthalmitis in participating European countries.

ESCRS STUDY DESIGN

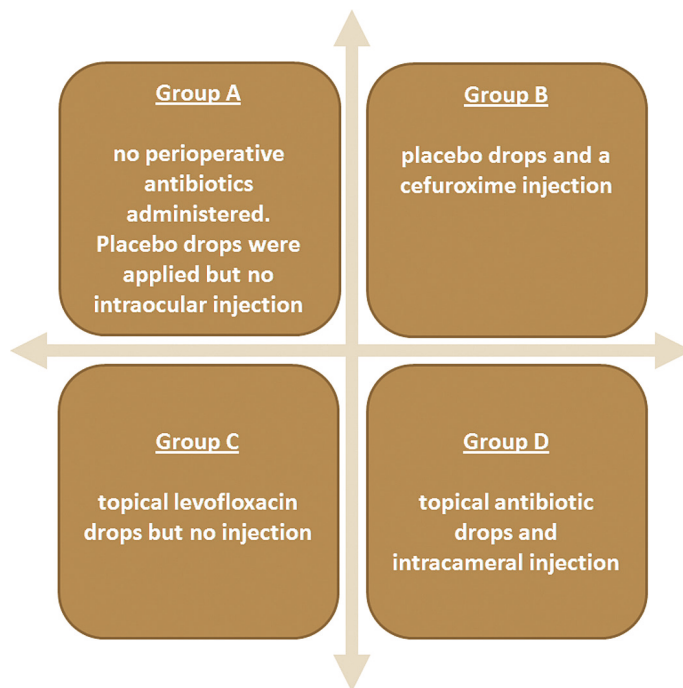
The ESCRS study evaluated effects of an intracameral injection of cefuroxime 1mg at the close of surgery, and compared postoperative endophthalmitis rates with other study groups that included perioperative antibiotic drops, and controls. Study groups are shown in Table 10 opposite. Conducted with over 16,000 patients in 23 medical centres in 9 European countries, the ESCRS study was able to delineate the prophylactic effect of four interventions using a 2x2 factorial design in prospective, randomized fashion. For ethical reasons, there was no placebo intracameral injection; however, the administration of topical antibiotic drops (levofloxacin) was masked.

All 4 study groups received standard preoperative PVI (povidone-iodine), as well as topical levofloxacin drops four times daily (QID) postoperatively for 6 days. The group (Group A) that received only these basic treatments was considered the “control” group, as ethical principles mandated this be a “minimum treatment” group rather than an absolute control. The variables were 1) the intracameral injection of 1mg cefuroxime at the close of surgery, and 2) the administration of an intensive pulsed dose regimen of 3 drops levofloxacin, each drop separated by 5 minutes, also given at the close of surgery, along with two drops given preoperatively, 30 minutes apart (at 30 and 60 minutes before surgery). The study design permitted cross-comparisons of the 4 study groups.

The endpoint of the study was infective endophthalmitis, whether proven or presumed. Samples were taken for laboratory testing from the anterior chamber and vitreous cavity, for Gram-stain, culture and PCR (polymerase chain reaction). If any of the 3 laboratory tests were positive, the patient was considered to have proven infective endophthalmitis.

The ESCRS study added the use of PCR to traditional laboratory methods of Gram stain and microbiological culture to identify causative organisms in cases of postoperative endophthalmitis. Samples from 24 ophthalmology units were sent to 9 microbiology laboratories and 2 European molecular biology laboratories (Regensburg, Germany and Alicante, Spain). From the 29 cases of presumed endophthalmitis in 16 603 patients, 20 cases had proven infective endophthalmitis via one

Table 10. ESCRS Study 2X2 Factorial Design



or more of the testing methods. Of these, 14/20 were culture-positive with all but one also positive by PCR. The remaining 6/20 were positive by PCR but negative by Gram-stain or culture. Nine of 29 patients remained negative via any testing method.

RESULTS OF THE ESCRS STUDY

The ESCRS study found that the risk for contracting postoperative endophthalmitis was significantly reduced, approximately 5-fold, by an intracameral injection of 1mg cefuroxime at the close of surgery ($p=0.001$ for presumed endophthalmitis; $p=0.005$ for proven endophthalmitis). Among the 4 ESCRS study groups, the lowest incidence rate was observed in Group D, where both intracameral cefuroxime and peri-operative topical levofloxacin were used. This rate was 0.049% for presumed endophthalmitis, and 0.025% for proven endophthalmitis. Endophthalmitis rates in the 4 study groups are presented in Table 11.

Five cases of endophthalmitis did occur in cefuroxime-treated groups in the ESCRS study. These included 3 isolates of coagulase-negative staphylococci (CNS) classified as resistant to cefuroxime (see Microbiology Section above). On sub-analysis, the benefit of cefuroxime was stronger against causative streptococcal strains than against CNS strains, although some additive effects may have occurred between the cefuroxime and topical levofloxacin drops.

Although conducted throughout various countries in Europe, no cases of MRSA and no cases of endophthalmitis due to Gram-negative organisms were encountered in

the ESCRS study, and no cases of endophthalmitis due to streptococcal strains occurred in cefuroxime-treated groups.

An important observation in these results was the proportion of streptococcal infections, where virulent strains of these organisms that exude exotoxins, or toxic byproducts, are especially destructive to ocular tissues. This is evident in Table 12, where visual outcomes are compared in cases of infection from staphylococcal vs streptococcal infections. Infection due to streptococci had earlier onset and resulted in poorer visual outcome¹¹.

Aside from the essential findings surrounding the value of the intracameral injection, the study also evaluated certain risk factors. The use of CCI vs scleral tunnel technique was associated with a 5.88-fold increase in risk of postoperative endophthalmitis; silicone IOL optic material (compared to acrylic) a 3.13-fold increase; and surgical complications a 4.95-fold increase. The more experienced surgeons, and male patient gender were also associated with higher endophthalmitis rates.

Characteristics of endophthalmitis cases were described in a subsequent publication¹¹. The time to onset of signs and symptoms in the 29 cases of endophthalmitis that occurred across all 4 study groups is shown in Table 13. There were

no cases of early-onset (1-3 days) endophthalmitis in the ESCRS study groups receiving intracameral cefuroxime. Among the 7 cases occurring between 4-7 days, 5/7 occurred in study groups not receiving intracameral cefuroxime. Cases presenting from 8-14 days included one proven endophthalmitis case in Group B (*S. epidermidis* associated with poor wound healing); one unproven case treated with cefuroxime was associated with a

surgical complication. Two late-onset (>14 days) proven cases and two unproven cases all occurred in control Group A that did not receive intracameral cefuroxime. A comparison of ESCRS and EVS findings in this regard are further discussed in the section on diagnosis of acute endophthalmitis below.

Table 11. Endophthalmitis incidence in ESCRS study groups¹

<p>Group A</p> <p>Intent to Treat Number of patients 4054</p> <p>Incidence Rates (%) Total: 0.345 (95% CI, 0.119-0.579) Proven: 0.247 (95% CI, 0.118-0.453)</p> <p>Per Protocol Number of patients 3990</p> <p>Incidence Rates (%) Total: 0.326 (95% CI, 0.174-0.557) Proven: 0.226 (95% CI, 0.103-0.428)</p>	<p>Group B</p> <p>Intent to Treat Number of patients 4056</p> <p>Incidence Rates (%) Total: 0.074 (95% CI, 0.015-0.216) Proven: 0.049 (95% CI, 0.006-0.178)</p> <p>Per Protocol Number of patients 3997</p> <p>Incidence Rates (%) Total: 0.075 (95% CI, 0.016-0.219) Proven: 0.050 (95% CI, 0.006-0.181)</p>
<p>Group C</p> <p>Intent to Treat Number of patients 4049</p> <p>Incidence Rates (%) Total: 0.247 (95% CI, 0.119-0.454) Proven: 0.173 (95% CI, 0.070-0.356)</p> <p>Per Protocol Number of patients 3984</p> <p>Incidence Rates (%) Total: 0.251 (95% CI, 0.120-0.461) Proven: 0.176 (95% CI, 0.071-0.362)</p>	<p>Group D</p> <p>Intent to Treat Number of patients 4052</p> <p>Incidence Rates (%) Total: 0.049 (95% CI, 0.006-0.178) Proven: 0.025 (95% CI, 0.001-0.137)</p> <p>Per Protocol Number of patients 4000</p> <p>Incidence Rates (%) Total: 0.050 (95% CI, 0.006-0.181) Proven: 0.025 (95% CI, 0.001-0.139)</p>

Study group treatments are described in Table 3

Table 12. Visual outcomes related to bacterial strains in ESCRS study

<p>STAPHYLOCOCCAL INFECTIONS</p> <p>Final VA range in 11 cases: 6/6 - 6/24 (20/20 - 20/80) No cases legally blind, ie: 6/60 (20/200) or less</p>
<p>STREPTOCOCCAL INFECTIONS</p> <p>Final VA range in 8 cases: range 6/6 - no light perception (NLP) 5 cases legally blind All 5 cases due to Streptococci None of the 5 cases had received cefuroxime</p>

Table 13. Time to onset of signs and symptoms in 29 cases of endophthalmitis (ESCRS study)

DAYS TO ONSET	CASES		
	Total	Proven	Unproven
1 - 3	9	8	1
4 - 7	9	7	2
8 - 14	7	3	4
> 14	4	2	2

Adapted from reference 11

8 UPTAKE OF INTRACAMERAL CEFUROXIME AS PROPHYLAXIS OF POSTOPERATIVE ENDOPHTHALMITIS

Figure 2 on page 9 shows the number of sites and countries that have reported benefit of intracameral cefuroxime as routine prophylaxis during cataract surgery. In addition, these reports attest to the dramatic drop in endophthalmitis rates after the practice was initiated. Aside from centres in the 9 countries included in the ESCRS study, Sweden, France, South Africa, Singapore, and a region of the United States, report routine use of intracameral cefuroxime or another antibiotic at the end of cataract surgery.

As a result of findings in Sweden, Swedish surgeons now routinely administer an intracameral injection of 1 mg cefuroxime in 0.1ml Normal Saline at the end of phacoemulsification surgery. The technique, developed in Sweden^{12, 13}, has now generated data from over 1 million patients^{3, 5}, where both retrospective and prospective studies support the efficacy of the intracameral cefuroxime injection.

A recent report¹⁴ surveyed the rate of uptake of intracameral cefuroxime injection at the end of cataract surgery across Europe. A total of 193 ophthalmic surgeons participated

in the survey; 74% stated they always, or usually, use intracameral antibiotics in cataract procedures. This reflects a substantial rise from the approximate 60% usage rate cited in the 2010 ESCRS member survey [Leaming 2011], and up from the 55% utilization rate of cefuroxime cited for ophthalmic surgeons in the UK in 2009 [Gore 2009]. The uptake of intracameral antibiotics in the United States based ASCRS membership, in the same Leaming 2010 survey, lagged behind, near 23%, and had not increased substantially from the 2007 data [Chang 2007]; nevertheless, approximately 82% of ASCRS respondents stated they would likely use intracameral antibiotics if commercially available. The most frequently cited reason for non-use was simply the lack of commercial availability of a suitable product.

Preferred practice guidelines issued by the American Academy of Ophthalmology in 2011 state “only intracameral antibiotics at the end of the case guarantees suprathreshold antibiotic levels for an extended period of time.” (AAO)

CEFUROXIME

Cefuroxime is in the class of beta-lactam antibiotics with strong activity against important Gram-positive bacteria commonly implicated in postoperative endophthalmitis such as *Streptococcus* spp. and *Staphylococcus* spp. (except MRSA, MRSE and *Enterococcus faecalis*). It acts by inhibiting bacterial cell wall synthesis by binding to PBP (penicillin binding protein) sites, leading to bacterial cell lysis. Many Gram-negative bacteria are susceptible (except *Pseudomonas aeruginosa*).

Aprokam[®] was recently approved by the European Medicines Agency (EMA), the European equivalent of the FDA, and is available as a commercial product that contains cefuroxime 50mg powder for solution and for intracameral injection at the end of cataract surgery. The product was marketed in 2012 with an indication for the antibiotic prophylaxis of postoperative endophthalmitis after cataract surgery, and at the time of this writing was available in 16 European countries with plans for expansion into 5 additional countries through 2014. The vial is intended for single use of an injected dose of 1 mg cefuroxime in 0.1 ml volume.

The product circular describes the following breakpoints as epidemiologic cut-off values (ECOFF) for cefuroxime:

- *Staphylococcus aureus*, ≤ 4 mcg/ml
- *Streptococcus pneumoniae*, ≤ 0.125 mcg/ml
- *Escherichia coli*, ≤ 8 mcg/ml

- *Proteus mirabilis*, ≤ 4 mcg/ml
- *Haemophilus influenzae*, ≤ 2 mcg/ml

Use of an alternative agent is recommended for patients at risk of infection with resistant strains such as MRSA. The Aprokam[®] circular (www.medicines.co.uk) also cites mean intracameral cefuroxime levels of 2614 +/- 209 mg/l (10 patients) at 30 seconds and 1027 +/- 43 mg/l (9 patients) at 60 minutes after drug administration¹² (note that mg/l is equivalent of mcg/ml).

When cefuroxime was initially chosen years ago as intracameral prophylaxis, a number of features distinguished it from “first generation” cephalosporins such as cefazolin. As a “second generation” cephalosporin, its spectrum of antibacterial activity extended to a number of Gram-negative microbes where activity was superior to first generation cephalosporins.

Cefuroxime is bactericidal in action, with bacterial killing effects related to the amount of time where cefuroxime levels exceed microbial MICs. Maximum killing effects with cephalosporins occur at 4-5 times the MIC, so that cephalosporins can also be considered “concentration-dependent” agents as well as “time-dependent” antibiotics. Neither cefuroxime nor cefazolin are indicated against MRSA/E or *Enterococcus faecalis*. Use in penicillin-allergic patients is discussed in Section 15 of these Guidelines. Cefuroxime, which does not share similar side chains with penicillin, is safer to use in penicillin-allergic patients than

other cephalosporins such as cefazolin (further discussed in Section 15 of these Guidelines).

If cefuroxime is not commercially available, and extemporaneous compounding is necessary, guidelines for preparation appear below and in Appendix I. Extemporaneous compounding should utilize cefuroxime in a licensed parenteral product, diluted to a concentration of 10mg/ml with sterile 0.9% normal saline (to deliver the dose 1 mg/0.1ml for intracameral injection).

After ensuring that the incision is watertight cefuroxime is injected at the close of surgery.

Note: The intracameral application of antibiotics, including cefuroxime, vancomycin, aminoglycosides or others, may not be licensed by regulatory authority and thus may be given at the surgeon's discretion. Clinicians should be aware of country-specific implications as regards liability, medical insurance and reimbursement.

Other antibiotics used intracamerally

Use of other antibiotics by intracameral injection is also described in the literature, but certain drawbacks exist for several of these. Vancomycin is highly effective against Gram-positive, but essentially ineffective against Gram-negative bacteria. This important antibiotic should be reserved for cases of resistant Gram-positive strains, such as MRSA, and not used casually or for widespread prophylaxis, although intracameral use is reasonable in MRSA carriers who require cataract surgery. Gentamicin has activity against many Gram-negative strains, notably *Ps. aeruginosa*, and also against some staphylococci, but has poor activity against *P. acnes* and streptococci (the latter being important, virulent and toxin producing strains among endophthalmitis isolates). On occasion, combination therapy is used where specifically needed and preparation guidelines for many agents are included in Appendix I.

The ESCRS survey published in 2011 [Leaming] showed that 66.3% of respondents were using intracameral antibiotics. Of these, 80.3% were using cefuroxime, 12.9% vancomycin, and 6.8% moxifloxacin.

9 RISK FACTORS FOR POSTOPERATIVE ENDOPHTHALMITIS IDENTIFIED IN THE ESCRS STUDY

Certain risk factors increase rates of postoperative endophthalmitis after cataract surgery, although these are also difficult to quantitate and vary among reported series. Risk factors identified in the ESCRS study and related Odds Ratios are shown in Table 14.

A) CLEAR CORNEA INCISION AND POSTOPERATIVE ENDOPHTHALMITIS

The clear cornea incision (CCI) technique is historically thought to have contributed to an increased incidence of endophthalmitis after phacoemulsification surgery, due to postoperative changes in IOP that may create suction and subsequent inflow of extraocular fluid and particles into the anterior chamber. In a large meta-analysis, Taban and associates [Taban 2005] identified CCI in phacoemulsification as a risk factor during the time period 1992 - 2003 where increased endophthalmitis rates of 0.189% were seen, as compared with rates of 0.074% observed after scleral tunnel incisions.

This risk factor (CCI) was assessed prospectively in the ESCRS study, with similar results. Patients receiving the CCI procedure were found 5.88 times more likely to contract endophthalmitis than patients undergoing the scleral tunnel technique. These results must be viewed with caution, however, because only two of the participating 24 centres used scleral tunnel incisions routinely, with none of the others using it more than occasionally.

One important factor appears to be construction of the tunnel. With a CSI (corneo-scleral incision), the tunnel is more quadratic, whereas with CCI the proportions are often double in width compared to radius, and thus more prone to gaping. Therefore, the increased risk associated with CCI may be reduced by suturing the corneal incision [Masket 2005]. However, recent experimental work challenges this belief, noting that a well-constructed unsutured stepped incision allows for less inflow than a sutured one [May 2013] but, again, the quality of the suturing could also come into question.

In a 2006 extensive review, Lündstrom stated there is no conclusive evidence of the relationship between clear corneal incision and endophthalmitis [Lündstrom 2006]. Data from the Swedish National Cataract Register that included 225 471 cataract extractions between January 2002 and December 2004, showed only a trend for a higher risk of endophthalmitis with CCI⁵. A more recent

Table 14. Risk factors identified in the ESCRS study

Risk Factor	Odds Ratio
Intra-cameral injection of cefuroxime – given or not given	4.92
Clear cornea (and position) versus scleral tunnel incision	5.88
Type of wound closure – suture or sutureless	no evidence found
Insertion of IOL – injector or forceps	not retained as a risk factor
Type of IOL material	3.13
Diabetic or non-diabetic	no evidence found
Immuno-suppression or not	no evidence found
Equipment sterilisation – disposable vs reusable	no evidence found
Complications of surgery	4.95

publication from the Swedish National Cataract Register³ does not mention CCI as a risk factor for endophthalmitis. Improvement in incision technique and the use of prophylactic intracameral cefuroxime may contribute to the reduction of this risk.

B) CHOICE OF INTRAOCULAR LENS

In a series of cases in Sweden between the years 1994-2000, Wejde and associates observed that silicone IOLs were associated with a higher postoperative rate of endophthalmitis as compared with heparin-surface-modified PMMA IOLs [Wejde 2005]. The ESCRS study had a similar finding. Patients receiving a silicone IOL were 3.13 times as likely to contract postoperative endophthalmitis than patients receiving an acrylic (or other material) IOL. Both the hydrophobic nature of silicone and surface biofilms on the IOL may be related to this finding, with biofilm formation and microbial persistence a topic of current interest. In contrast, there are studies that have not shown an increase in the rate of endophthalmitis when comparing acrylic and silicone IOLs [Nagaki 2003].

C) SURGICAL COMPLICATIONS

As in other studies, surgical complications were associated with a higher rate of postoperative endophthalmitis in the ESCRS study, where the risk was increased 4.95 fold when surgical complications occurred. While these may be difficult to quantitate, the recent Swedish report³ found that communication with the vitreous was a risk factor associated with a 3.65 fold increase in postoperative endophthalmitis rates.

In earlier reports, intra-operative capsular defect with vitreous loss was associated with a 14-17 fold increase in risk for endophthalmitis [Menikoff 1991, Wallin 2005].

10 PREOPERATIVE ANTISEPSIS

A) POVIDONE-IODINE (PVI)

More than any other form of preoperative antiseptics, the literature supports the essential role of PVI for ocular surface preparation prior to cataract surgery. Topical PVI as a form of prophylaxis for cataract surgery has become a standard of care (Table 15).

A mandatory step to reduce bacteria in the wound area is to apply povidone iodine 5-10% to the cornea, conjunctival sac and periocular skin for a minimum of three minutes prior to surgery. Where povidone iodine is contraindicated (true allergy is rare and hyperthyroidism only a relative contraindication to this singular use), aqueous chlorhexidine 0.05% may be used.

Early data showed that near 90% of ocular surface flora were reduced with use of PVI [Apt 1984] and the literature continues to support PVI as the primary evidence-based preoperative intervention to reduce postoperative endophthalmitis rates [Speaker 1991, Cuilla 2002, Wu 2006, Carrim 2009, Quiroga 2010, Ferguson 2013].

Investigators have examined the use of different PVI concentrations with varying results. There may be increasing interest in the time/kill profile of PVI against microbial strains currently isolated from endophthalmitis cases, but this type of data remains sparse [Hosseini 2012]. Because of current interest in variations in PVI use, the bibliography in these Guidelines includes a number of literature references on this topic.

Nevertheless, complete sterilization of the ocular surface should not be expected, with PVI alone, or with addition of topical antibiotic drops (discussed below), and bacterial contamination of the aqueous humor in the range of 2 to >40% is reported in the literature in large series of patients, despite preoperative measures.

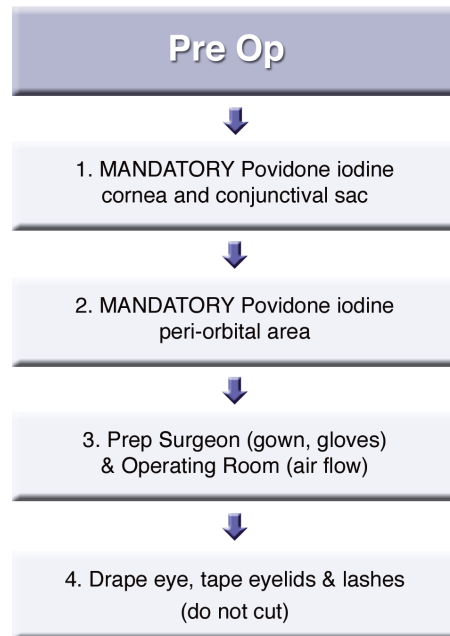
It is important to note that PVI should not be used or injected inside the eye due to corneal endothelial cell toxicity.

B) PREOPERATIVE TOPICAL ANTIBIOTIC DROPS IN ADDITION TO PVI

Despite the widespread use of topical antibiotic drops prior to surgery, some clinicians opt not to use preoperative antibiotic drops at all, while others believe they have a role.

The recent report from Sweden by Friling and associates³ examined the value of add-on topical antibiotics in a subset of patients, and concluded that use of topical drops preoperatively and/or postoperatively had no proven benefit over chlorhexidine 0.05% (PVI at one site only) preoperatively and with intracameral cefuroxime/antibiotic injected at the close of surgery. In the 85% of the patients who received only cefuroxime (not add-on antibiotics), the postoperative endophthalmitis rate

Table 15. Summary of key preoperative antiseptics steps



was 0.025%. Add-on antibiotics were given immediately (within an hour) preoperatively or postoperatively as single or repeated instillations. In the 10% of these cases where only preoperative antibiotics were added on, the endophthalmitis rate was 0.017%. In the group receiving add-on postoperative antibiotics, the rate was 0.019%; the group receiving both pre-and postoperative add-on drops, the rate was higher, 0.041% (and higher than the group receiving intracameral antibiotic with no add-on topical drops). None of these rates were statistically significantly different from the intracameral injection group (and no antibiotic drops).

Increasing the frequency or duration of preoperative antibiotic drops was investigated by He and associates (2009), who did not find greater reduction of conjunctival flora when a fourth generation fluoroquinolone drop was administered QID for 3 days vs 1 day. Moss and associates (2009) also found no difference in conjunctival flora reduction following PVI when a fourth generation fluoroquinolone was added QID for 3 days; 4% (PVI eyes) and 8% (gatifloxacin + PVI eyes) of conjunctival cultures still remained positive. These reports underscore that not only has no clear benefit been established for the administration of antibiotic drops preoperatively, but that bacterial resistance may be induced, and complete bacterial eradication on the ocular surface is not achieved.

Nevertheless, antiseptics with PVI or chlorhexidine is mandatory to reduce ocular surface colony counts as much as possible prior to cataract surgery.

11 OPERATING THEATRE

The operating theatre should be equipped with standardized quality control systems, with separate clean and dirty circuits for all personnel and equipment or materials. Quality assurance of air flow and surfaces should be performed periodically.

AIR FLOW DESIGN

Airflow systems should be equipped with the proper filters (HEPA) and undergo regular maintenance. The operating theatres should be under positive pressure, with doors remaining closed except for transfers. No current guidelines or data are available describing airflow systems that best prevent post-operative endophthalmitis after phacoemulsification. However, history shows, by comparing the DNA profiles of bacteria from vitreous isolates with those collected from the lid and skin flora of the patient, that in the case of ECCE procedures, 85 per cent of endophthalmitis cases were traced back to the patient himself [Speaker 1991].

There is also an additional risk of eye infection from bacterial flora of the surgical team, transferred via an airborne route. Established aerobiology data suggest that a hospital operating theatre should have a minimum of 20 air changes per hour in order to reduce airborne bacterial counts; however, this is somewhat arbitrary since all airborne bacteria, attached to skin scales, will settle to the floor in still air after 30 minutes. Research on ultra-clean air for hip surgery shows that a fast laminar flow of air in the operating theatre can remove airborne bacteria within seconds, rather than the minutes required with traditional airflow systems that change air at 20 changes per hour. Nevertheless, it is unclear whether this degree of ultra clean air would be required for phacoemulsification surgery through a very small incision.

This issue was addressed in the ESCRS multi-centre study of endophthalmitis after phacoemulsification surgery, as some clinical partners operated with minimal airflow, others with 20 air changes per hour, and yet others with ultraclean air systems utilizing either horizontal or vertical laminar flows. Results, however, were inconclusive and the relationship between air changes per hour and incidence of postoperative endophthalmitis is not yet established.

EQUIPMENT – STERILISATION AND SINGLE-USE

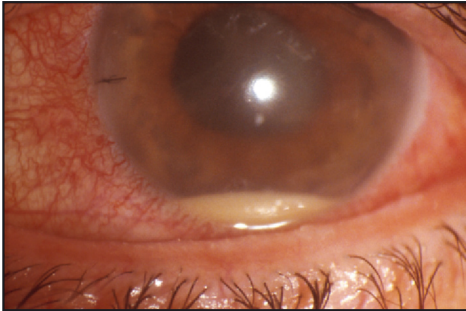
All instruments for surgery should be sterile. Limitation to single-use is even more important, as incidents have occurred where instruments were not washed properly prior to sterilisation, which may itself also have been faulty. Great care is required in both the washing and autoclaving of instruments, as the latter process is never absolute nor an exact science! Both procedures should be scrutinized in any ongoing 'epidemic' of postoperative endophthalmitis where strains of skin bacteria, viz. coagulase-negative staphylococci, are identified in the surgical unit for no apparent reason. A cleaning and sterilization protocol, similar to the one proposed by the ASCRS, should be established and carefully followed [Hellinger 2007].

Single-use of tubing and other equipment that becomes wet during the operative procedure is always preferable, if cost allows. Tubing is not easily sterilised in an effective manner unless an ethylene oxide gas steriliser is available. Bottles of solution, such as BSS (balanced salt solution), should never be kept or used for more than one operating session. Any air vents applied to these bottles should be protected with a bacterial filter. Remember that wet areas are easily contaminated with *Pseudomonas aeruginosa*, an organism that can lead to devastating endophthalmitis.

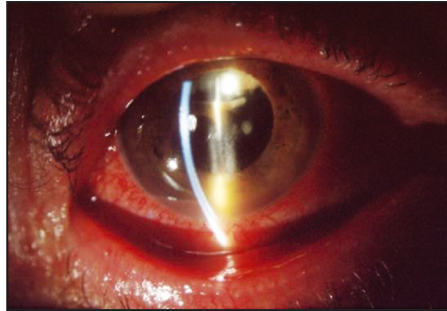
Endophthalmitis outbreaks: In a review of the literature, Pathengay and associates (2012) reported the most common cause of endophthalmitis outbreaks were contaminated solutions (37%) and contaminated phacoemulsification machines (22.2%) followed by ventilation systems (11.1%), defective sterilization (11.1%) and others. Gram-negative bacteria outnumbered Gram-positive bacteria as pathogens in these cases of external contamination sources, with *Ps. aeruginosa* accounting for 51.8% of Gram-negative isolates. In this review, the most common source for outbreaks was irrigating solutions used perioperatively.

Outcomes after *Ps. aeruginosa* endophthalmitis are especially poor. This microorganism was identified in an outbreak in India, found in the phacoemulsifier's internal tubes, the PVI solution, and the operating theatre air-conditioning system. Isolated strains were multi-drug resistant to cefazolin, chloramphenicol, tetracycline, aminoglycosides and fluoroquinolones (but most were susceptible to polymyxin B). PCR identified one cluster with 94% similarity, and other isolates shared 88% similarity, to the air-conditioning isolate. Ten of the 20 patients involved had enucleation or phthisis of the infected eye [Pinna 2009].

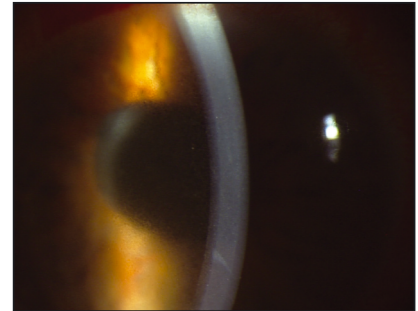
12 DIAGNOSIS AND TREATMENT OF ACUTE AND CHRONIC ENDOPHTHALMITIS



Acute endophthalmitis with hypopyon



Chronic sacular endophthalmitis (Note whitish plaque) TASS
Courtesy Dr Augusto Abreu



A) DIAGNOSIS

Postoperative endophthalmitis is conventionally characterized as either acute, occurring within 6 weeks of cataract surgery or chronic, occurring after that period of time.

The majority of patients with acute postoperative endophthalmitis present within 1-2 weeks after surgery, with signs and symptoms of rapidly progressive intraocular inflammation. Time to presentation and clinical characteristics, according to the EVS¹⁰ and ESCRS⁷ studies, are described in Tables 16 and 17, respectively.

Two recent large series of acute endophthalmitis cases after cataract surgery describe substantially different mean times to presentation - 5 days [Pijl 2010] vs 13 days [Lalwani 2008] - with the latter possibly reflecting an altered mechanism of onset associated with clear cornea surgery.

In the ESCRS Endophthalmitis study, proven endophthalmitis cases presented within a shorter period of time and most occurred in the study groups that did not receive cefuroxime; in the EVS study, 50% of cases due to other (other than CNS) Gram-positive and Gram-negative microbes appeared within the first two postoperative days.

Pain, swollen eyelids and media haze were associated with proven cases in the ESCRS study. In the EVS study, where retinal vessels could be seen at presentation, two-thirds of cases showed equivocal or no growth and no Gram-negative microbes were found on culture. EVS study eyes presenting with VA of light perception only, corneal-wound abnormalities and loss of red reflex were more likely to harbor Gram-negative or other Gram-positive microorganisms [Wisniewski 2000].

Acute infectious postoperative endophthalmitis is initially a clinical diagnosis, considered presumed until proven by positive gram stain, culture or PCR. If a patient presents with sudden decrease in visual acuity early after cataract surgery, often with pain and signs of diffuse intraocular inflammation (vitreous infiltration, hypopyon, red eye), infectious endophthalmitis should be suspected (see Section D - TASS versus infective endophthalmitis). B-scan

Table 16. Time to presentation of postoperative endophthalmitis

DAYS TO ONSET	EVS	ESCRS
1-3	24%	31%
4-7	37%	31%
8-14	17%	24%
>14	22%	14%

Adapted from reference 11 and Wisniewski 2000.

Table 17. Presenting clinical characteristics of postoperative endophthalmitis

	EVS	ESCRS
BLURRED VISION	94 %	92.9%
PAIN	74 %	79%
SWOLLEN EYELIDS	34 %	46.25%
HYPOPYON	75-85 %*	72%
RED EYE	82 %	**
MEDIA HAZE	79 %	63%

**75% in 854 screened patients with clinical diagnosis of endophthalmitis; 85% in eligible patients. Other characteristics remained similar for both patient categories. ** Not evaluated as red eye.
Adapted from reference 11 and Wisniewski 2000*

ultrasonography can be a useful adjunct to confirm vitreous involvement and rule out complications such as retinal detachment, especially in an eye with opaque media.

While endophthalmitis should be confirmed with laboratory microbiology testing, once the clinical diagnosis of endophthalmitis is made, there is no time to waste. The clinician should proceed immediately to

collect an intraocular sample and administer empirical antibiotic treatment by intraocular injection. Presumed endophthalmitis should be considered a medical emergency because bacteria are replicating exponentially and their toxic by-products, with associated inflammation, are destroying visual potential. Beware of delaying the diagnosis with a trial of corticosteroid drops unless there is strong suspicion of a sterile origin (TASS).

An anterior chamber tap should be performed to obtain an aqueous sample, and a needle tap, vitreous biopsy or pars plana vitrectomy to obtain the vitreous sample. Following EVS recommendations, a pars plana vitrectomy should be performed in cases presenting with visual acuity of light perception only, but we also favor this technique for acute cases presenting with better vision as it allows a larger sample to be obtained, removes much of the bacterial load in the vitreous (the main source of acute inflammatory effect) and reduces the need for reoperation. (In 65% of the EVS tap/biopsy eyes the sample was obtained using a vitrector rather than a needle; once the probe is inside the eye, performing a core vitrectomy is just one step away.)

In severe cases, the procedure should be performed within the hour; however, an operating room may not be available within this timeframe. In the outpatient clinic, we recommend the availability of a cutting device for the vitreous biopsy because a needle tap is too frequently dry, and sucking material from the vitreous cavity in a severely inflamed eye may lead to complications. (In the EVS study, a higher rate of retinal detachment was not found in the tap-biopsy group; however, as previously stated, most of those samples were obtained with a vitrector.)

B) MICROBIOLOGY TESTING

Aqueous and vitreous samples are delivered to the forewarned microbiologists for Gram-stain culture and microbial sensitivity testing, with instructions to deep-freeze a sample for polymerase chain reaction (PCR) if not available on-site. Samples may be sent in the original syringe or in sterile Eppendorf tubes. If the Gram stain and culture are negative after 24 to 48 hours, the sample reserved for PCR analysis can be dispatched to the relevant laboratory.

Gram Stain

Stains, Gram for bacteria and others such as calcofluor when fungi or other pathogens are suspected, are useful because they can offer immediate confirmation of the infectious nature of this postoperative inflammation. In the EVS study, Gram stain was positive in 43% of vitreous samples and in 19% of aqueous samples; in the ESCRS study, Gram stain detected 5 out of 8 streptococcal infections.

Microbiology, Cultures

Ideally, samples should be plated directly onto culture media but, if not possible, blood culture bottles (particularly paediatric ones) offer a useful option [Joondeph 1989, Kratz 2006]. In the EVS study, two solid media (chocolate agar and saboraud dextrose agar) and a broth (enriched thioglycollate) were used. Strict criteria defined a “confirmed positive culture” (CPC) and a “laboratory confirmed infection” (LCI), giving an overall positivity rate of 69%, with undiluted vitreous the best sample source (Tables 18 and 19). Similar culture media were used in the ESCRS study, with a positivity rate of 48%, which increased to 69% when PCR was taken into account. Note that cultures must be retained for at least 15 days to detect any slow growing microorganisms. Antibiotic susceptibility testing (requiring 24-48 hours time) can be performed with isolates from the initial cultures, or directly using the RAST method [Miño de Kaspar 2002] (requiring 6-10 hours).

Table 18. Positive cultures in the EVS study¹⁰ (Barza 1997)

EVS	
LABORATORY CONFIRMED GROWTH	69%
EQUIVOCAL GROWTH	13%
NO GROWTH	18%

Table 19. Rate of positive cultures in EVS¹⁰ samples (Barza 1997)

EVS	CPC	LCI	ONLY SOURCE
AQUEOUS	22.5%	26.9%	4.2%
UNDILUTED VITREOUS	54.9%	58.9%	21%
VITRECTOMY FLUID			8.9%

C) PCR

PCR, with broad range primers targeting highly conserved regions of eubacterial 16S rDNA (18S rDNA for fungi), can detect and amplify minute amounts of bacterial DNA that are subsequently sequenced and identified. It offers much improved pathogen detection, especially in the case of chronic endophthalmitis with low pathogen counts [Hykin 1994, Lohmann 1998]. In the ESCRS study, PCR tests were carried out centrally and replicated independently at two centers, yielding 6 additional positive cases that were negative by Gram stain or culture.

However, the increased risk of contamination due to the high sensitivity of the method, along with the absence of antibiotic sensitivity testing and the partial lack of quality control standards in routine diagnostic laboratories, have limited its routine use thus far.

Some centres have direct access to PCR; alternatively, samples can be deep frozen for identity of the microorganism at a future time (i.e. if the cultures are negative but an infectious origin is suspected). In this case, samples can be sent for PCR analysis at a later date. One drop of aqueous humor and one drop of vitreous humor

should be placed in separate sterile Eppendorf plastic tubes and stored at +4°C for up to 24 hours, or frozen at -20°C for longer periods of time, then sent by next-day courier service to the laboratory. Expert PCR testing for bacteria and fungi is available from Dr. Udo Reischl, Institute for Medical Microbiology and Hygiene, University Hospital, 93053 Regensburg, Germany (udo.reischl@klinik.uni-regensburg.de; Tel: +49-941-944-6450).

Recently, quantitative real-time polymerase chain reaction (qPCR), where DNA amplification and detection of the target sequence occur together which decreases handling of PCR products and risks of contamination, has been used for postoperative endophthalmitis [Goldschmidt 2009, Bispo 2011]. It is performed using fluorescent probes, with the level of fluorescence proportional to the degree of accumulation of double-stranded PCR product, and with a quantitative measurement of the microbial load available in 90 minutes. Clinical applications are currently limited but may become more of an option in the future with the adoption of commercial kits for quick confirmation of the infectious or sterile nature of the postoperative inflammation.

D) TASS VS INFECTIOUS ENDOPHTHALMITIS

Toxic Anterior Segment Syndrome (Tass)

Toxic anterior segment syndrome (TASS) is a sterile postoperative inflammatory reaction caused by a non-infectious substance that enters the anterior segment and results in toxic damage to intraocular tissues [Mamalis 2006].

TASS can occur after uneventful anterior segment surgery, either as isolated cases or as a cluster. It is often confused with endophthalmitis because of a similar clinical picture (poor vision, hypopyon, fibrin). However, some distinguishing characteristics help to differentiate between an infectious origin or a toxic origin, and permit selection of appropriate treatment: corticosteroids for TASS and antibiotics for endophthalmitis. Distinguishing features of TASS include:

- Early onset (as early as 12-24 hours postoperatively)
- Limbus-to-limbus corneal edema, secondary to widespread damage of the endothelial cell layer
- Iris damage (fixed, dilated or irregular pupil, iris transillumination defects)
- High IOP (intraocular pressure), due to trabecular meshwork damage
- Absence of vitritis (the most important feature of TASS because it involves primarily anterior segment inflammation, whereas endophthalmitis involves the posterior segment)
- Usually improves with corticosteroid treatment

Three main causes of TASS may be categorized as follows:

- Extraocular substances that inadvertently enter the AC during or after surgery (eg. topical povidone-iodine).
- Products introduced into the AC as part of surgical procedure, such as balanced salt solution (BSS) with manufacturing lot errors in pH or osmolality (or with agents added in the operating room), or anaesthetics (only preservative-free lidocaine 1% is safe). Any medication injected into the eye should be preservative-free and used at the proper concentration to avoid toxic reactions.
- Irritants on instruments that have accumulated due to inadequate instrument cleaning and/or sterilization (eg. denatured OVDs retained in reusable instruments, heat-stable endotoxins, sulphate impurities from autoclave steaming). Problems with the instrument cleaning process, especially inadequate flushing of ophthalmic instruments and handpieces, enzymatic detergents, and ultrasound baths remain the most common factors associated with TASS [Bodnar 2012].

TASS treatment involves intensive topical corticosteroids (and sometimes oral). IOP and endothelial cell count should be monitored. Gonioscopy should be performed. Immediate anterior chamber washout is controversial and usually not performed.

There are 3 sight-threatening complications of TASS:

- Permanent corneal decompensation
- Intractable glaucoma
- Cystoid macular edema

An outbreak of TASS is an environmental and toxic control issue that requires complete analysis of all medications

and fluids used during surgery, as well as complete review of operating room and sterilization protocols. The first recorded TASS outbreak occurred in Massachusetts in 2005; investigation showed that patients had received a BSS that had become contaminated with high levels of a sterile endotoxin. As a result of this outbreak, the ASCRS TASS task force was formed, which launched a TASS reporting questionnaire to record details of surgical procedures, in order to help trace the causes of TASS cases or outbreaks. This questionnaire is available at <http://tassregistry.org/tass-combined-survey.cfm>

As noted, finding the cause of TASS requires scrutiny of the entire surgical process. The following steps may be necessary:

- Multiple changes to surgical procedures or surgery may need to stop altogether.
- Increased utilization of disposal instruments.
- Proper instrument cleaning and sterilization protocols may need to be put in place (e.g. an important step includes flushing all reusable cannulas immediately after surgery). It is important to follow recommendations such as those specified by the ASCRS TASS Task Force [Hellinger 2007].

To shield our practices from TASS, constant vigilance of all surgical procedures is required along with a prompt response should this problem arise.

E) TREATMENT OF ACUTE POSTOPERATIVE ENDOPHTHALMITIS

The diagnosis of postoperative endophthalmitis is considered a medical emergency requiring investigation and treatment within an hour of presentation, especially in severe cases.

As described in the section on diagnosis, there is ongoing discussion on whether to perform a vitreous tap (with a vitrector or needle) or to perform a vitrectomy. As stated earlier, we favor performing a diagnostic and therapeutic vitrectomy (our “gold standard”) in most cases.

The EVS recommended performing a vitrectomy only in cases presenting with visual acuity of light perception (LP) only. However, with technical advances in vitrectomy, more recent retrospective series have shown better visual outcomes with broader use of a full vitrectomy in postoperative endophthalmitis cases, including those presenting with better than LP visual acuity (more recently, 91% \geq 20/40 final VA, vs 53% in the EVS) [Kuhn 2005, 2006].

Some clinicians favour performing only a vitreous tap, avoiding the need for an operating room and more sophisticated equipment, for the sake of delivering prompt intravitreal antibiotic injection; however, the respective reported visual outcomes here are similar to those of the EVS study (51.6 % \geq 20/40 final VA) [Pijl 2010]. It should be noted that direct comparisons between such studies cannot be made due to differences in study design, inclusion/exclusion criteria and reported microbial spectrum.

In an ideal world, a vitreoretinal surgeon and staffed operating room would be instantly available but this ideal world rarely exists. Reality is, therefore, a balance of time over completeness.

If a vitreoretinal surgeon and equipped operating room are available, then a formal three-port core or complete vitrectomy is performed on the principal “Ubi pus ibi evacuat.” A core vitrectomy leaves residual vitreous base sepsis whilst more complete vitrectomy carries the risk of iatrogenic retinal detachment which is potentially disastrous.

This choice is at the discretion of the vitreoretinal surgeon. Intravitreal antibiotics and steroids are injected slowly at the end of the surgery.

The best technique to obtain an adequate vitreous sample, after an aqueous tap and possible AC cleanup, is:

- 1) The infusion port is inserted through the pars plana 3-3.5 mm from the limbus (pseudophakic eye), but is not turned on.
- 2) The vitreous cutter is inserted through a separate 3-3.5 mm sclerotomy and directly visualized through the pupil.
- 3) A hand-held syringe is attached to the aspirating line and the surgical assistant slowly aspirates whilst the surgeon activates the cutter until an adequate sample (at least 0.5 ml) is obtained (the eyeball softens and the cutter is disappearing from view).
- 4) After checking that the infusion cannula is properly placed inside the vitreous cavity, the infusion is then turned on to reform the globe and the cutter removed.
- 5) The syringe now contains 0.5- 2 ml of infected, but undiluted, vitreous and is promptly sent to the laboratory.

Proceeding to a core or full vitrectomy:

- 6) The vitreous cutter is now connected to the machine for aspiration control and a light pipe is inserted through the pars plana. With this setup in place, only a small amount of extra time is needed to complete a standard three port vitrectomy within the limits of visualization, and without going further, in order to avoid risks of a retinal break in these oedematous retinas. (Some authors advise performing a total vitrectomy with posterior vitreous detachment (PVD) induction if not already present; however, we believe that, in these acute endophthalmitis cases, this intervention should be reserved for skilled vitreoretinal surgeons).
- 7) It is useful to perform a posterior capsulotomy with the cutter to improve visualization and to permit flow through the entire eye, which facilitates recovery.

Once the vitrectomy is as complete as possible, the intravitreal antibiotics are injected through one of the sclerotomies with a 25-30G needle. Consider reducing the dose by 50 per cent if a full vitrectomy has been performed. This injection should be given slowly, over 1-2 minutes, into the mid-vitreous with the needle, bevel up, aiming away from the macula. Separate syringes and separate needles, lest flocculation occur, are used through an existing entry site. Intravitreal dexamethasone (preservative free) is then injected.

It is mandatory to have available the drugs and recipe for their dilution in both operating and emergency rooms used for this purpose (see preparation guide).

Warning microbiologists that a sample is coming, and alerting the pharmacologist that drug preparation is required in the appropriate dilution for intravitreal injection, is of benefit during the normal working day but is rarely available after-hours.

The procedure is usually performed under peri-bulbar, retro-bulbar or general anaesthesia, but not topical because the patient has too much pain or lack of cooperation.

When the “gold standard” procedure is not possible due to lack of a vitreoretinal surgeon and vitreoretinal operating room, in order to avoid delays, an appropriate option is to perform a vitreous biopsy with injection of intravitreal antibiotics without further therapeutic vitrectomy (our “silver standard”). As simple aspiration with a needle is frequently unsuccessful, it can be performed using a portable vitrector (eg: the Intrector, commercially available from Insight Instruments, Inc., Stuart, FL). (Nowadays, there are some full-function vitrectors that are small enough to be easily transported and set up, and could be used in any surgical area.) After sampling, antibiotics and corticosteroids are injected through the sclerotomy, as above. With current transconjunctival small gauge probes, incision frequently does not require suture closure. Every cataract surgeon and duty resident must have the skills to perform the biopsy and intravitreal injections.

It is also important, after surgery, to continuously chase the laboratory for microbial culture and sensitivity results and not wait for “the hospital post”.

Following emergency room tap/antibiotics, the patient should be reviewed clinically after six hours. Patients often get worse before they get better, but always get worse before they get worse! Following core or complete vitrectomy, review is at 12 hours.

Topical antibiotics (fortified), steroids and mydriatics (atropine) are initiated after the surgery. Dilating the pupil at the end of the surgery to avoid permanent synechiae is critical; atropine should be used because cyclopentolate alone is inadequate (a permanently stuck pupil seen at the first post-op dressing is most frustrating).

Once intravitreal antibiotics are administered there is doubt about the role of topical antibiotics, but they may be especially useful in cases with surface problems.

Subconjunctival antibiotics probably don't give any additional benefit and in many cases are withheld.

Preparation Guide

An antibiotic combination is injected separately intravitreally and repeated as necessary, according to clinical response, at intervals of 48 to 72 hours depending on the degree of drug retention after injection. In most cases intravitreal antibiotics need to be administered only once to control the infection (7% of EVS patients received a repeat intravitreal antibiotic injection between 36-60 hours). Repeated injections are reported to increase the retinal toxicity of intravitreal antibiotics [Oum 1992].

Intravitreal antibiotic doses must be highly accurate because the margin for error between chemotherapy and toxicity is narrow, especially for aminoglycosides (gentamicin, 200 µg is effective but 400 µg may be toxic, causing macular infarction). Since initial therapy should cover both Gram-positive and Gram-negative microorganisms, the most common antibiotic combinations are as follows:

First choice: vancomycin (1mg) plus ceftazidime (2mg)

Second choice: vancomycin (1mg) plus amikacin (0.4mg), specifically in β-lactam sensitive patients (see discussion on allergy under prophylaxis and Section 15 of these Guidelines). Despite the synergy between vancomycin and amikacin for Gram-positive microbes, many surgeons are abandoning the use of aminoglycosides for treating Gram-negative bacteria because of the risk of retinal toxicity.

Antibiotics that have been used relatively safely for intravitreal injection are shown in Table 20 opposite. The Table lists non-toxic doses of antibiotics; however, consider reducing the dose (some would suggest by 50%) if a full vitrectomy has been performed, since the vitreous would have prevented rapid diffusion of antibiotics towards the retina. In addition, silicone oil and gas-filled eyes require a substantial dose reduction (1/4-1/10 of the standard dose has been suggested) taking into account the reduced fluid distribution volume that remains in the eye [Hegazy 1999].

The antibiotics for intravitreal injection should be supplied, freshly diluted, by the hospital pharmacy department. However, for emergency cases, a method for diluting the drugs in the operating theatre is provided in Appendix I.

Due to potential antibiotic physical or chemical incompatibility issues, it is important to use separate syringes and needles for each drug to be injected (antibiotics and steroid) and not mix the drugs together in the same syringe. Most incompatibilities are physical in nature - that is, they produce a precipitate (as opposed to invisible chemical inactivation or degradation) - and the more concentrated the solutions, the more likely they are to produce a precipitate when mixed.

Up to 0.1 ml of solution for injection can be lost in the hub of the syringe and needle when drugs are diluted or prepared for injection into the eye.

Always draw up a sufficient volume of drug to fill about half a 1 ml syringe (e.g. 0.4 – 0.5 ml). Then place the needle you will use to inject into the vitreous (30G) onto the syringe. Take care not to leave any air in the syringe and needle

pathway, and discard the excess drug so that just 0.1 ml remains for the injection.

In this way, the surgeon will inject only what is in the syringe and will not need to look continuously at the barrel to assure that only the needed 0.1 ml is injected.

Dexamethasone (preservative-free) is often given by intravitreal injection (dose = 400 µg in 0.1ml volume, using the commercial preparation containing 4 mg/ml) but should not be mixed with antibiotics in the same syringe. It produces, accompanied with antimicrobial therapy, a more rapid reduction of intraocular inflammation; however, there is conflicting evidence about its effect on visual outcome, as results from several studies report a range of results from negative effect [Shah 2000] to no effect [Das 1999] to a beneficial effect [Gan 2005, Albrecht 2011].

The use of intravitreal dexamethasone may reduce the need for systemic (oral) corticosteroids in elderly patients, thereby avoiding the side effects of these systemic agents. Intravitreal dexamethasone treatment is supplemented with topical and often injected periocular steroids.

Adjunctive Systemic Antibiotics

Intravitreal injection of the antibiotic provides the highest drug concentration “at the target site” but levels remain for only a limited time period. For this reason, we believe that severe acute purulent endophthalmitis should be treated

with additional systemic antibiotic therapy with the same drugs used for intravitreal therapy. This adjunctive regimen will help maintain meaningful intravitreal levels of the drug for a longer period of time by counterbalancing the diffusion of injected drug out of the eye. There will also be enhanced penetration into the eye from the systemic circulation, facilitated by the now inflamed ocular membranes. High systemically administered doses are optimal, but there is need to be cautious of risks for systemic toxicity. Systemic vancomycin levels should be monitored if administered intravenously.

Antibiotic therapy may be modified after 24 to 48 hours according to the clinical response and the antibiotic sensitivity profile of the cultured microorganism. However, the ocular inflammation usually becomes worse before becoming better, even under the correct antibiotic regimen. Consider referral to a vitreoretinal surgeon for an opinion on a full vitrectomy if response is poor after a partial/mini core/”silver standard” vitrectomy; then, intravitreal injection of antibiotics would be repeated. If systemic antibiotic therapy was administered, it is possible that additional intravitreal antibiotic injections will not be needed, thereby avoiding the potential toxicity of repeated intravitreal injections.

Table 21 summarizes the steps outlined above for the clinical diagnosis, perioperative and postoperative management of acute endophthalmitis after cataract surgery.

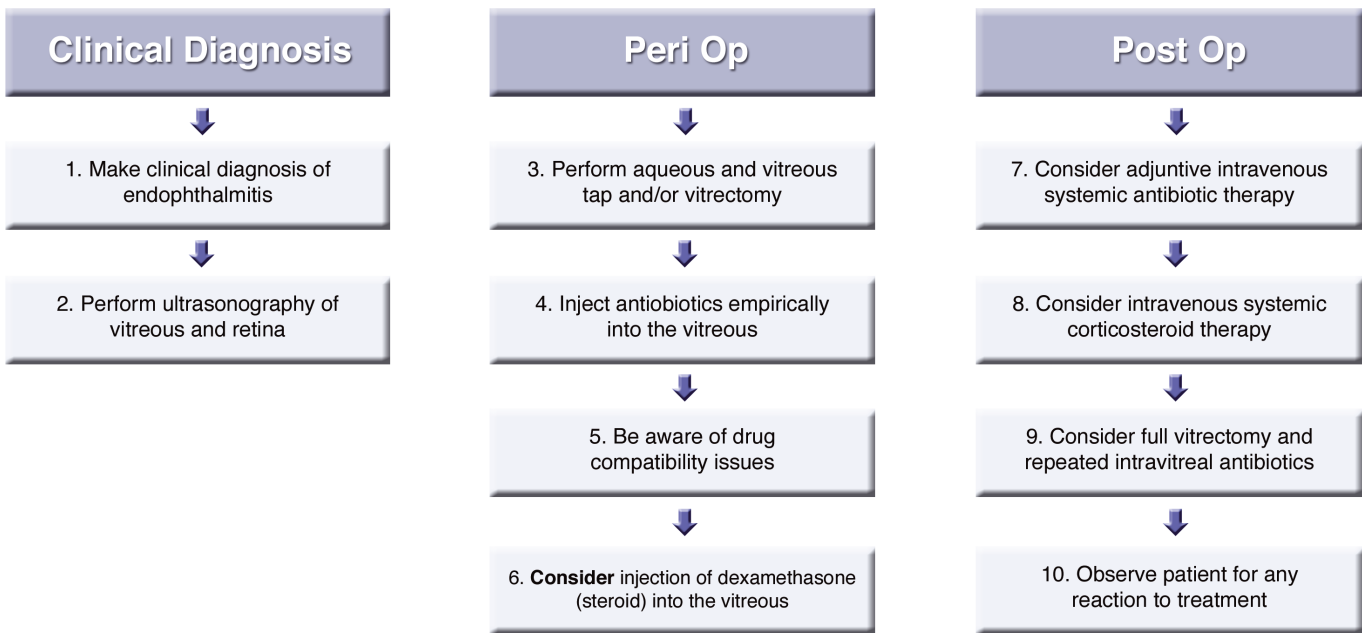
Table 20. Common doses for intravitreal antibiotic injection

Antibiotic	Intravitreal dose* (µg)	Duration (h)**	Vitreous Half-life (h)
Amikacin	400	24-48	24
Ampicillin	2000 (2 mg)	24	6
Amphotericin	5 or 10	24-48	6.9–15.1
Cefazolin	2000 (2 mg)	16	7
Ceftazidime	2000 (2 mg)	16-24	16
Cefuroxime	2000 (2 mg)	16-24	
Clindamycin	1000 (1 mg)	16-24	
Erythromycin	500	24	
Gentamicin	200	48	12-35
Methicillin	2000 (2 mg)	16-24	3-5
Miconazole	5 or 10	24-48	2
Moxifloxacin	50-160		1.72
Oxacillin	500	24	
Vancomycin	1000 (1 mg)	48-72	30
Voriconazole	100		2.5

Adapted from selected references including Peyman GA, Lad EM, Moshfeghi DM. Intravitreal injection of therapeutic agents. *Retina* 2009; 29: 875-912. **

Duration of meaningful levels as described in literature reports.

Table 21. Treatment of Postoperative Acute Endophthalmitis



F) CHRONIC SACULAR ENDOPHTHALMITIS

This chronic or late form of post-cataract endophthalmitis may appear weeks, months or even years after surgery, making diagnosis more challenging. Clinically, it presents as a chronic, insidious and recurrent granulomatous iridocyclitis, that initially responds to topical steroids, but relapses when steroids are tapered. Some clinical signs include:

- Large keratic precipitates
- Small hypopyon
- Mild anterior vitritis (characteristic of *S. epidermidis*)
- Whitish plaque (residual lens material and bacterial colonies) within the capsular bag (characteristic of *P. acnes*). Chronic late endophthalmitis is often called Chronic Saccular Endophthalmitis, because the microorganism is inside the capsular bag or sac.

The infectious nature of this late postoperative inflammation was initially described by Meisler and associates (1986) who presented a thorough description of this form of endophthalmitis.

When faced with an insidious postoperative inflammation, it is important to differentiate between infectious and sterile causes, such as lens induced uveitis or IOL related inflammation in order to implement appropriate therapy [Ozidal 2003, LeBoyer 2005].

Chronic saccular endophthalmitis is usually caused by low virulence microorganisms from the patient's own normal saprophytic flora. About two-thirds of cases are due to *Propionibacterium acnes*, but *Staphylococcus epidermidis* (CNS), *Corynebacterium* spp and fungi, among

others, are also implicated. Cultures should be followed for at least 15 days because these are fastidious growing microorganisms.

Due to the localized nature of this infection in the capsular bag, with too few free bacteria to be conveniently detected by culture, PCR has become a very useful test because it can detect minute quantities of bacterial DNA. In a study by Lohmann and associates (2000) the causative pathogen in clinically diagnosed chronic endophthalmitis cases was identified in the aqueous humour in 84% of eyes by PCR as compared with 0% by culture. In the vitreous samples, the pathogen was identified in 92% of eyes by PCR compared with 24% by culture.

If the decision is made to operate on these patients, capsule fragments should be collected for histopathologic and electron microscopy studies which can reveal the presence of intra-cellular Gram-positive bacteria within macrophages lining the capsule. This fact, already described in the initial paper by Meisler and associates (1986) has led to proposals for new therapeutic alternatives (further discussed opposite). In contrast to acute postoperative endophthalmitis, which is a medical emergency, there is more time to make a proper diagnosis and choose therapeutic options when faced with a possible case of chronic postoperative endophthalmitis. A few facts should be taken into consideration:

In chronic saccular endophthalmitis, the microorganisms are isolated in the capsular bag and protected by a biofilm; they may also become intracellular within macrophages, out of reach of common antibiotics used to treat acute endophthalmitis. However, some antibiotics, such as clarithromycin, are well absorbed orally, penetrate well into

the eye, have anti-biofilm properties and are concentrated within PMNs and macrophages, where they are better able to kill intra-cellular Gram-positive bacteria. Some studies [Warheker 1998, Karia 2001) have found the use of clarithromycin effective, and a dose of 500 mg bid for 2-4 weeks is recommended. The addition of vancomycin irrigation of the capsular bag has improved the response rate in cases of infection with *Propionibacterium* spp. [Pellegrino 2005).

Several surgical options are available for managing chronic endophthalmitis, should a more invasive course be necessary:

- Antibiotic irrigation of the capsular bag, at the initial AC tap or at a subsequent intervention in culture positive cases
- Injection of intravitreal antibiotics (IOAB)
- Pars plana vitrectomy (PPV) with IOAB
- PPV with partial capsulectomy (PC) and IOAB
- PPV with total capsulectomy (TC), IOAB, IOL removal or exchange (IOLx)

Table 22 outlines recurrence rates of chronic endophthalmitis after each treatment type (Deramo 2001, Aldave 1999, Clark 1999). It shows that the more aggressive the treatment, the lower the recurrence rate. However, delaying more aggressive treatment does not seem to have a negative effect on final visual outcome, so that more conservative treatments can be tried initially.

Table 22. Recurrence of chronic endophthalmitis after treatment

Treatment	Clark (n=36)	Aldave (n=25)	Overall (n=61)
IOAB	12/12	1/2	13/14 93%
PPV	5/10	5/10	10/20 50%
PPV + PC	2/14	4/9	6/23 26%
PPV + TC + IOLx	0/12	0/13	0/25 0%

Adapted from Deramo et al. 2001.

Based on these facts, our suggested approach is as follows:

- To determine the microbial source, take an AC tap and withdraw 0.1 ml for culture and PCR. Consider vancomycin irrigation (30 µg / ml) of the capsular bag, trying to reach the area of the capsular plaque if present. A vitreous tap is not usually performed initially (the AC

tap can be performed at the outpatient clinic) but can be done surgically at a later time, if needed.

- Begin treatment with oral clarithromycin 500 mg bid for 2-4 weeks. Consider adding oral moxifloxacin (400 mg daily for a week) as it also has good intraocular penetration and a broad spectrum of antimicrobial activity.
- When culture and PCR results are available (from 2 days to several weeks, depending on laboratory availability) different scenarios may emerge:
 - PCR – negative and culture - negative: Likely a non-infectious late postoperative inflammation; the case should be reassessed to find a possible origin (IOL or lens- induced).
 - PCR-negative and culture-positive: Likely a contamination because PCR false – negatives are uncommon; however, caution is advised. If the initial therapy fails, treat according to culture-antibiogram.
 - PCR and culture-positive: Assuming that both tests are consistent, the microorganism is identified, along with antibiotic susceptibility. If the initial treatment with clarithromycin (and possible vancomycin irrigation) failed, additional antibiotic treatment may be implemented (intraocular – systemic) according to the antibiogram. If there is no resolution, surgical options should be considered.
 - PCR-positive and culture-negative: Here, a microorganism has been identified, with some idea of its susceptibility pattern, even without a specific antibiogram for this strain. We can proceed in a similar way as in PCR and culture-positive cases.

If surgical options are necessary, one likely begins with a PPV with partial capsulectomy, trying to eliminate as much of the whitish plaque as possible, without compromising the IOL stability. Attempt to collect samples of capsule fragments for histology, electron microscopy and microbiology investigation. Additional intravitreal antibiotics (vancomycin, cefuroxime, cefazolin - depending on antibiogram) and systemic therapy (clarithromycin, moxifloxacin) should be given for an additional week. Intravitreal antibiotics or pars plana vitrectomy alone are not recommended because of high recurrence rates.

If this initial surgery fails, it will be necessary to remove the IOL, collect samples of capsule fragments, and perform a full three-port pars plana vitrectomy. (This situation is not acute endophthalmitis with associated fragile and edematous retina, but a chronic one). A secondary iris or sulcus fixated IOL can be considered. Additional antibiotics are administered.

13 INTRAVITREAL ANTIBIOTICS

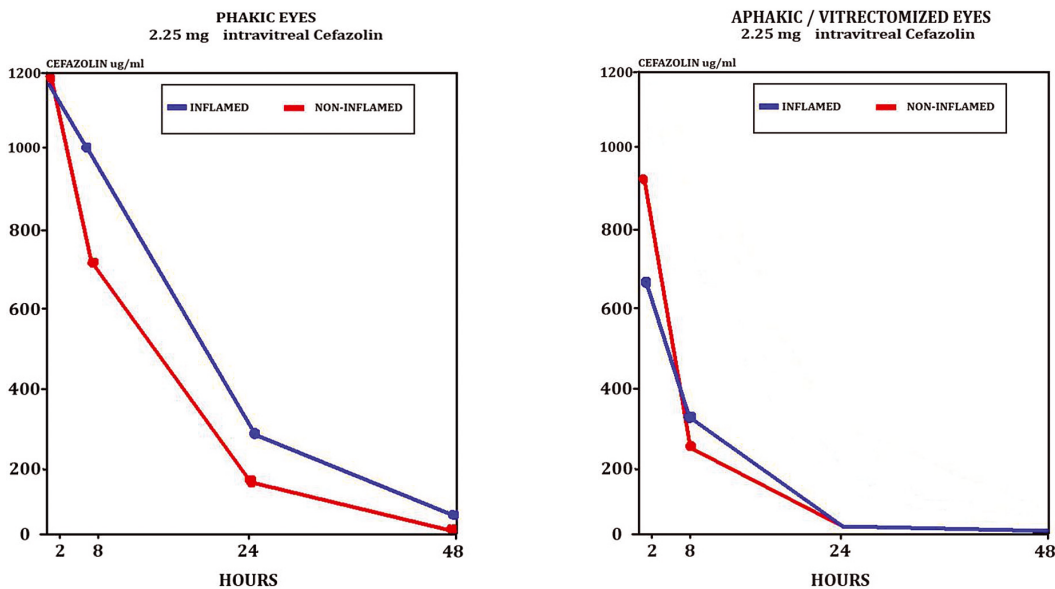
The intravitreal injection is considered a standard of care for the management of postoperative endophthalmitis. It is the only means by which high levels of antibiotic can be delivered to the vitreous cavity. Because a single intravitreal intervention is preferred, doses as high as can safely be injected are chosen, so that antibiotic levels are sustained above bacterial MICs for as much time as possible. Treatment, as early as possible, is also very important as, with time, bacteria replicate, may exude toxins, and changes occur in the avascular microenvironment of the

vitreous, such as pH, that may impact antibiotic efficacy.

An intravitreal injection delivers the highest safe bolus of injection, but then antibiotic levels slowly decline over time in the vitreous cavity; this rate of removal is affected by the surgical status of the eye, the degree of inflammation, and the specific antibiotic agent involved.

Figure 3 shows that the rate of antibiotic removal from vitreous, in an animal model, was faster in eyes that had undergone vitrectomy and were aphakic.

Figure 3. Drug elimination rates in vitreous



Adapted from Ficker et al. 1990.

METHOD OF PREPARING THE INTRAVITREAL INJECTION

Instructions for proper dilution of antibiotic in commercially available vials to arrive at the correct intravitreal dose are presented in Appendix I of these Guidelines. Each commercial product includes specific instructions for dilution, and these should be reviewed prior to proceeding with instructions in Appendix I. It is worth mentioning that manufacturers' instructions often direct that initial dilution of the vial be made with sterile water (not with normal saline). This initial dilution with water is appropriate for the reconstituted higher concentration that results within that vial, because these products are intended for parenteral use and the solute itself contributes to tonicity of the reconstituted solution.

In these Guidelines, dilution with normal saline is cited throughout all dilution procedures (not sterile water initially). This is recommended in order to simplify the use of sterile water vs normal saline and avoid confusion with two different diluents. Note that once the commercially available product has been diluted multiple times, with normal saline, to a much lower concentration than is intended for systemic injection, the differences in tonicity are washed out. However, the clinician should be aware of the reasons behind instructions to dilute initially with water vs saline and examine the products to be used accordingly. If in doubt, consult a hospital pharmacy that is accustomed to such procedures. (Dilution with BSS is not recommended because of the added solutes already present in that product).

Choice of antibiotic products

Preservatives, such as benzyl alcohol, are contained in some commercial antibiotic products, but are not desirable for intravitreal injections, and these products should be avoided during extemporaneous compounding of intravitreal injections. Injectable products commercially available for intrathecal injection typically do not contain harmful preservatives. These are preferred wherever possible for intravitreal injection - but pay close attention to differences in concentration between products intended for parenteral vs intrathecal injection.

A few cautionary statements

There are no short cuts to proper dilution, selection and separation of antibiotics for intra-vitreous injection. The literature describes attempted use of a single 1cc syringe to draw up small amounts of several agents for intravitreal injection, all in one syringe. This practice is inappropriate because the commercial products used remain undiluted, along with the preservatives and other components. Aside from potential drug incompatibility issues, direct contact of these concentrated solutions with internal parts of the eye is more likely to result in toxic effects.

Only doses and agents proven safe for use in the eye (as established in previous animal models) and substantiated

by clinical use should be used inside the eye. There is no place for “experimentation” of any kind here, or for transfer of doses assumed to be correct because “similar” compounds have been used in a particular dose.

Because all agents prepared extemporaneously for injection into the eye must meet standards for “injectable” drugs, the clinician is advised to maintain good access to professionals who are accustomed to handling and preparing these agents. Central locations such as hospital pharmacies have manuals with extensive data on compatibility and safety of agents intended for parenteral injection, and are the starting point for exploring how to adapt these agents for the eye. These centres are more than happy to provide professional guidance, and are the starting place for inquiries into the safety of any proposed injectable dose that is not clearly defined in the ophthalmic literature.

Hospital pharmacies have reference manuals detailing the compatibility or incompatibility of mixtures of injectables in various concentrations. For example, a mixture of ceftazidime 1mg/ml and vancomycin 20mg/ml are known to be compatible (assuming known vehicles), whereas, if the concentration of ceftazidime were to be increased to 10, 50 or 200mg/ml, a physical incompatibility could occur resulting in a precipitate. Understanding such principles and limitations helps the surgeon to navigate the steps needed to prepare injectables for delivery inside the eye.

14 ADJUNCTIVE SYSTEMIC ANTIBIOTIC TREATMENT

Injection of antibiotic directly into the vitreous (intra-vitreous injection) is the mainstay of treatment for postoperative endophthalmitis. Once this intervention became established as the standard of care for treatment of endophthalmitis, the value of added systemic antibiotics was questioned, since animal experiments showed that very little, if any, antibiotic penetrated into the vitreous space from the systemic circulation.

These animal experiments were often not able to replicate conditions that occur inside the eye after cataract surgery, ie: inflammation, aphakia and vitrectomy. They also usually failed to measure vitreous levels after several doses, or several days of intravenous therapy in the animal models that were used; typically, vitreous antibiotic levels were measured after only a single intravenous dose.

However, when clinical conditions were, in fact, duplicated in animal models, results showed a substantial rise in intravitreal antibiotic concentrations in the aphakic, vitrectomized eye after multiple systemic antibiotic doses. As seen in Figures 4A and B, vitreous antibiotic levels can climb within one or two days, and may attain meaningful levels at about 24 to 48 hours, just as vitreous antibiotic levels from the intravitreal injection are beginning to decline.

Delivery of antibiotic into the vitreous by direct intravitreal injection is usually sufficient to treat the majority of endophthalmitis infections. However, if the infection is severe, the surgeon may use his judgment and add systemic antibiotics, broad spectrum initially, and subsequently according to bacterial susceptibility and patient safety. The use of adjunctive systemic antibiotics was discussed in Section 12 above, suggesting use in severe acute purulent endophthalmitis, using systemic antibiotic therapy with the same drugs used for intravitreal therapy (See Section 12, “Anti-microbial therapy”).

According to the randomised, multi-centre “Endophthalmitis Vitrectomy Study” (EVS)¹⁰, systemic antibiotics did not appear to have any effect on the course and outcome of endophthalmitis after cataract operations. However, the study design used different drugs systemically (amikacin and ceftazidime) from those used intravitreally (vancomycin and ceftazidime), which does not contribute towards maintaining effective antibiotic levels within the eye. Thirty-eight per cent of the endophthalmitic eyes demonstrated Gram-positive cocci, against which ceftazidime has limited activity, whereas vancomycin could have been more effective. Thus, adjunctive systemic antibiotic therapy

with the same antibiotics as those given intravitreally is recommended for management of acute virulent bacterial endophthalmitis.

For fungal infection, intravitreal amphotericin (5-10 µg) or voriconazole (100 µg) are usually associated with administration of the same drug systemically. Fungal endophthalmitis is particularly difficult to treat, frequently requiring vitrectomy with removal of the IOL and capsular bag together with combination chemotherapy and with alternative antifungal drugs.

Intramuscular vs intravenous antibiotic injection

An intravenous dose of antibiotic produces much higher instantaneous blood levels than does an intramuscular injection. This higher concentration gradient helps to drive antibiotic into tissues or spaces such as the vitreous. Therefore, intramuscular injection is not advised if intermittent intravenous dosing is feasible.

Figure 4A, 4B

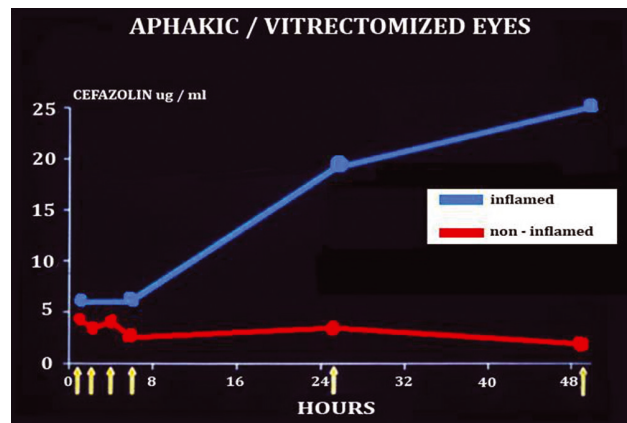
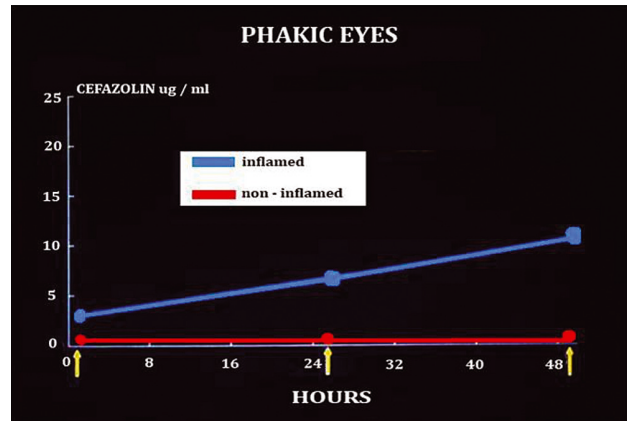


Figure A shows poor vitreous penetration in non-inflamed eyes, but a gradual increase in the presence of inflammation. However, aphakia and vitrectomy (Figure B) increase penetration even more substantially. Adapted from Martin et al. 1990.

15 DILEMMAS IN THE PREVENTION OF POSTOPERATIVE ENDOPHTHALMITIS

A) ALLERGY TO CEFUROXIME

The prevalence of penicillin allergy has been variously estimated, but these estimates often included patient reporting that may overstate both the nature and incidence of a true allergic reaction. The incidence of true penicillin allergy, as confirmed by skin testing, in patients claiming a penicillin allergy is only about 10-20% [Salkind 2001]. Some allergic manifestations may be mild, but a severe, true allergy to penicillin involves IgE-mediated immunologic responses that may lead to anaphylaxis. The incidence of penicillin anaphylaxis is estimated at 0.015-0.004% [Idsoe 1968].

However, there is interest in the cross-reactivity between penicillins and cephalosporins, and specifically, the risk of potential cross-allergenicity with cefuroxime. The true cross-allergenicity between penicillins and cephalosporins is lower than suggested in early reports, and is lower for the second to fourth generation cephalosporins than first generation cephalosporins. True cross-reactivity between penicillins and cephalosporins is now linked to the molecular configuration of the specific compounds in

question. When the cephalosporins carry side chains (R1 side chains) different than the penicillin in question, the chances of cross-reactivity are very low to negligible.

A number of cephalosporins, especially first generation cephalosporins because of their similar side chains, may show cross-reactivity with penicillin. These include familiar agents such as: cephalothin, **cefazolin**, cefaclor, cephalexin, and cephazolidine, among others. These do confer an increased risk of allergic reaction in patients who have a true penicillin allergy.

However, the group of cephalosporins that do not share the similar side chain with penicillin do not share this increased risk of allergic reaction or cross-allergenicity. These include cefprozil, **cefuroxime**, **ceftazidime**, and ceftriaxone, among others [Campagna 2012, Pichichero 2005, 2007].

In Sweden, every patient undergoing cataract surgery receives intracameral cefuroxime - unless the patient has a distinct allergy to cephalosporins, so that the focus of concern is allergy to cephalosporins, not allergy to penicillin.

Table 23. Rates of endophthalmitis with/without add-on antibiotic drops

Postop Endophthalmitis	Intracameral Antibiotics Only	+ Preop Topical Antibiotics*	+Postop Topical Antibiotics†	+ Preop and Postop Antibiotics‡
Cases/total	98/396,894	8/47,574	2/10,382	3/7,307
Percentage	0.025%	0.017%§	0.019%¶	0.041%

* Included 1 of the following agents: levofloxacin, gentamicin, chlormphenicol, fusidic acid
† Included 1 of the following agents: levofloxacin, fusidic acid, chloramphenicol
‡ Included chloramphenicol before and after the procedure or chloramphenicol before and fusidic acid after the procedure
§ P value = .29 versus intracameral group
¶ P value = .73 versus intracameral group
|| P value = .38 versus intracameral group
Adapted from Frilling et al. 2013, reference 3.

Skin testing in the setting of cataract surgery is impractical. If suspicion/evidence of penicillin allergy exists, intracameral cefuroxime may be given. In cases of suspicion/evidence of cephalosporin allergy, cefuroxime should not be used; here intracameral moxifloxacin or vancomycin is a justifiable option.

Two cases of anaphylaxis after use of intracameral cefuroxime have been reported. One patient, with a history of allergy to amoxicillin, became hypotensive and diaphoretic; and recovered after treatment for anaphylaxis (Villada 2005). Another patient, who reported allergy to penicillin, complained of redness and pruritus in the arms while in the recovery room after phacoemulsification surgery, where 1mg cefuroxime had been administered. Symptoms progressed to a drop in blood pressure and difficulty in breathing; after treatment, symptoms resolved [Moisseiev 2013].

B) CHOICE OF POSTOPERATIVE DROP REGIMEN

Few data exist to help define the best options for postoperative antibiotic drop administration, although this is a legitimate area of interest. Particularly where surgical complications occurred, where wound healing may be poor or the patient is at risk of nosocomial infection postoperatively, there may be rationale for antibiotic coverage in the early postoperative period.

Recent data suggested that postoperative topical antibiotic drops confer no added benefit over intracameral cefuroxime injection in reduction of postoperative endophthalmitis (Table 23). The 2013 report from the Swedish Cataract Register³ shows there was no statistical benefit from add-on topical antibiotics, either preoperatively, postoperatively, or both, when intracameral antibiotics were also used.

Other reports also show no increase in observed endophthalmitis rates after omitting postoperative drops [Raen 2013]. In the ESCRS study, the pulsed antibiotic drop regimen at the close of surgery (Group C) showed no statistical benefit over controls (Group A) and did not add significantly to the intracameral injection (Group D) although

a small trend was seen. A study simulating the pulsed drop dosing regimen of the ESCRS study [Sundelin 2009] subsequently recorded the highest AH levels reported to date (4.4 mcg/ml). (A comparison of AH levels after topical drops vs intracameral injection is presented in Appendix II of these Guidelines).

If antibiotic drops are administered in the immediate postoperative timeframe, many clinicians favor a vigorous approach initially, for a period of time, avoiding any tapering of antibiotic drops to discourage development of antibiotic resistance. Some surgeons prescribe frequent postoperative antibiotics when complications occurred or wound healing problems are anticipated. Note that topical PVI after surgery, and before wound healing is complete is discouraged due to the risk of intraocular toxicity should PVI enter the wound.

At present, the choice of postoperative antisepsis is at the discretion of the surgeon who can best evaluate the postoperative environment, whether complications occurred, and other risk factors relating to patient or procedure. Currently, fluoroquinolone drops are favored agents in some areas due to their relatively broad spectrum, ability to penetrate the corneal epithelium to some degree, and commercial availability. However, the rate of resistance to these agents is growing steadily, and time/kill profiles, described in Appendix II of these Guidelines, remind that drop delivery to the tears is inherently inefficient and may be inadequate to eradicate bacteria, especially in the anterior chamber.

Moxifloxacin vs Cefuroxime

Choice of intracameral antibiotic: cefuroxime or fluoroquinolone?

The literature (Espiritu 2007), (Arbisser 2008), (Lane 2008) describes use of intracameral fluoroquinolone (FQ) (moxifloxacin in particular), in lieu of cefuroxime, citing a broader spectrum of activity especially against Gram-negative bacteria, and the risk of cephalosporin allergy. The issue of cephalosporin allergy has been addressed above, showing that cross-allergenicity with penicillin is not

a concern with cefuroxime. Cases of anaphylactic reaction to moxifloxacin are also reported, although not specifically after intracameral injection (use of intracameral FQs remains low compared to cefuroxime at the present time).

The issue of spectrum of activity, however, invites discussion of time/kill profiles for these different agents compared with doses that are administered safely by intracameral injection. The increasing rate of resistance to fluoroquinolones is an additional factor, as discussed above.

The choice of moxifloxacin (or any other proposed antibiotic) vs cefuroxime for intracameral injection as prophylaxis at the close of cataract surgery should follow a checklist for consideration that includes the following:

Proof of efficacy in randomized, prospective clinical trials

At the present time, only cefuroxime is shown to produce a statistically significant reduction in postoperative endophthalmitis rates¹. Literature reports cite efficacy of moxifloxacin in selected series, but no comparisons to cefuroxime are published, and no randomized clinical trials have evaluated intracameral moxifloxacin. A growing database in the literature supports the efficacy of intracameral cefuroxime in lowering postoperative endophthalmitis rates, as shown above in these Guidelines.

Spectrum of activity

The criticism has been levied that agents such as moxifloxacin have a broader spectrum of activity than cefuroxime, especially against Gram-negative microbes. The incidence of MRSA/MRSE in endophthalmitis isolates, as well as *E. faecalis*, is also cited.

Practically speaking, one can begin by considering whether microorganisms outside the common spectrum of cefuroxime, such as Gram-negative strains, especially *Ps. aeruginosa*, methicillin-resistant strains, or *E. faecalis* (which is described more recently) are managed by the preoperative PVI application, whether they are likely to be intraoperative contaminants, or likely postoperative contaminants. The organisms causing endophthalmitis in the post operative period may vary among regions of the world, and the surgeon is advised to be aware of these trends.

When administered intracamerally, only agents without benzalkonium chloride (BAK) are candidates, because BAK is toxic to the corneal endothelium. Therefore, the potential efficacy of only moxifloxacin is discussed here, as moxifloxacin for intracameral injection is reportedly adapted from the preservative-free eye drop product. Appendix II describes bacterial killing times for fluoroquinolone agents with, and without, BAK. That section shows that long exposure times may be necessary for moxifloxacin (without BAK) to kill microbes commonly causing endophthalmitis. Even a concentration of 5000 mcg/ml (=5 mg/ml) required

a relatively long period of time to eradicate certain strains of bacteria, including methicillin-resistant strains. There is no evidence at the present time that the intracameral doses of 100-500 mcg moxifloxacin are more effective than cefuroxime in eradicating organisms commonly found in postoperative endophthalmitis. In terms of other microbes as potential pathogens, no data is available to show that the 100-500 mcg doses of moxifloxacin would be efficacious against those, after a single intracameral injection.

Currently, the intracameral doses described for moxifloxacin range from approximately 100 mcg to 500 mcg; in comparison, the dose of intracameral cefuroxime shown to be safe and effective is 1 mg, at least two times higher than moxifloxacin.

While no data describe the time/kill profiles of either moxifloxacin or cefuroxime in doses or time frames used for intracameral injection, results of the ESCRS study confirm the clinical efficacy of intracameral cefuroxime against most commonly encountered bacterial strains in postoperative endophthalmitis.

Commercial availability and production quality control

Intracameral cefuroxime has recently become available in Europe as Aprokam[®] indicated for prophylaxis of endophthalmitis after cataract surgery. This product is manufactured and approved by the European Medicines Agency (EMA) for intracameral injection. On the other hand, no approved product exists for intracameral moxifloxacin. Where moxifloxacin has been used intracamerally, clinicians reportedly utilized the commercially available eye drop (0.5% concentration), and withdrew a small dose from the eye dropper bottle for injection into the eye. While these eye drop products are manufactured to be sterile before opening, other specifications for injectables are not applied to eye drop products. Therefore, at the present time, only intracameral cefuroxime is available as an approved product, manufactured specifically for intracameral injection. This factor is a possible concern should medico-legal issues arise.

CHOICE OF INTRACAMERAL INJECTION, SUBCONJUNCTIVAL INJECTION OR TOPICAL DROPS

Appendix II includes comparisons of antibiotic levels in tears and aqueous humor in a normal eye, after topical drops, intracameral injection, and subconjunctival injection. In summary, the intracameral injection delivers antibiotic directly to the aqueous humor in concentrations far greater than are achieved after either topical drops or subconjunctival injection. Supplemental therapy with drops or subconjunctival injection are at the discretion of the surgeon, but an understanding of the comparative drug levels achieved and comparative pharmacokinetics will help to guide the decision-making process.

APPENDIX I PREPARATION OF INTRAVITREAL DOSES

All antibiotics should be prepared by the hospital pharmacy, with protocols in place for agents used in the Ophthalmology department and in operating rooms where eye surgeries are performed. Be certain these reflect the drug products available in your country, as products commercially for parenteral administration may vary between countries.

However, in cases of emergency, Guidelines for diluting antibiotics in the operating theatre are appended here.

All equipment must be sterile, with procedures performed on a sterile surface. Drugs should be mixed by inverting or rolling the bottle 25 times to avoid frothing.

Important “do’s” and dont’s” include:

- Never return diluted drugs to the same or original vial for further dilution
- Never dilute to greater than 1 in 10
- Use Normal Saline without preservatives for dilution
- Do not use syringes more than once
- Do not reuse bottles
- Avoid use of drug products containing preservatives, if possible
- Do not change any needles after all but 0.1ml dose for injection has been pushed out of the syringe. (Recall that some retention may occur within the hub of the needle - the “dead space” which may vary with syringe product.) Always draw up at least 0.5ml solution into a 1 ml syringe, and expel all but 0.1ml when the final delivery port is attached, so that a full 0.1ml containing the dose, will be injected into the eye.
- Do not point the needle towards the retina, but point it forward instead, injecting very slowly into the mid-vitreous space.
- Do inject the drugs slowly over 1 to 2 minutes

Prior to preparing the dilutions it is mandatory to check the amount of the antibiotic in the vial as the same antibiotic may be sold in different strengths in each EU country.

GENERAL NOTES FOR DILUTION PROCEDURES: The table overleaf presents dilution procedures and respective concentrations, with final intravitreal dose. To avoid repetition, the syringes, vials and equipment to be used are exemplified here in these sample instructions for diluting vancomycin:

Vancomycin: Intravitreal Dose = 1000µg. Reconstitute one vial of 250mg vancomycin by adding Sterile Normal Saline for Injection (0.9 per cent) up to a volume of 10ml in

a sterile bottle with lid. Mix well. Withdraw 2ml accurately and add to 3ml of Sterile Normal Saline in a sterile bottle with lid. Mix well (concentration now = 10mg/ml). Use 0.1ml = 1000µg intravitreal dose.

Amphotericin B: this does require sterile water and three series of dilutions as follows:

- 1) Use 50mg/ml vial. Reconstitute with 10ml Sterile Water for Injection. (Produces 5mg/ml concentration).
- 2) Take 1ml of this dilution, add to 9ml Sterile Water for Injection. (Produces 500mcg/ml concentration).
- 3) Take 1 ml of this second dilution, add to 9ml Dextrose 5%/Water. (Produces 50mcg/ml concentration).

Dose of 5mcg is contained in 0.1ml of last dilution. Note that some clinicians use a dose of 10 mcg.

If 50 ml bottles of saline are available the following method can be used [Cordoves 2001]:

Vancomycin - mix vial of 500mg with 5ml saline withdrawn from 50ml bottle, shake well and then return to 50 ml bottle. Dilution gives 10mg/ml (dose of 0.1ml contains 1mg).

Ceftazidime - mix vial of 1g (1000mg) with 5ml saline withdrawn from 50ml bottle, shake well and then return to 50 ml bottle. Dilution gives 20mg/ml (dose of 0.1ml contains 2mg).

Amikacin – vial of 500 mg / 2ml. Take 0.8 ml (= 200mg) and inject into 50ml bottle (0.8 ml of saline should be withdrawn beforehand for precise concentration), shake well. Dilution gives 4 mg/ml (dose of 0.1ml contains 400µg)

Additional notes on intravitreal doses:

Amphotericin B (5-7.5 µg), a fungicidal antibiotic available for intravitreal injection, has been the preferred antifungal agent in the setting of fungal endophthalmitis, but its spectrum does not cover all fungi. Voriconazole, a triazole, that has a broader spectrum of antifungal activity, good oral bioavailability and intraocular penetration, and is reported safe for intravitreal injection (100 µg), is nowadays being used routinely as a first-line antifungal therapy. There is a growing concern for resistance to antifungal agents.

Fungal endophthalmitis is often treated with different antifungal agents and combination therapies are common. While repeated intravitreal injections are usually required, the number and interval are not standardized, but related to clinical response. Systemic anti-fungal therapy is also needed, with 6 to 12 weeks of treatment generally recommended. The source of the infection should be identified and appropriate measures taken.

PREPARATION OF INTRAVITREAL ANTIBIOTIC INJECTIONS

Antibiotic	Vial size	Amount of initial diluent, to/with volume	Initial Concentration	Aliquot	Added to Volume Normal Saline	Final Concentration	Dose Ordered
AMIKACIN	500mg	to 10ml (NS)	50mg/ml	0.8ml	9.2ml	4mg/ml	400 mcg AMIKACIN
METHOD 2	500mg	Using 50ml bottle (see overleaf)					
AMPHOTERICIN^a	See special method overleaf						
CEFTAZIDIME	500mg	to 10ml (NS)	50mg/ml	2ml	3ml	20mg/ml	2000 mcg CEFTAZIDIME
METHOD 2	1 Gram (=1000mg)	5ml (NS)/50ml bottle (see overleaf)					
CLINDAMYCIN	300mg/2ml	+1ml NS to volume of 3ml	100mg/ml	1ml	9ml	10mg/ml	1000 mcg CLINDAMYCIN
GENTAMICIN							
METHOD 1	3000mcg/ml minim, use 2ml	+ 1ml NS to volume of 3ml	2000mcg/ml	0.1 ml	-----	[2000mcg/ml]	200 mcg GENTAMICIN
METHOD 2	40mg/ml (unpreserved)	-----	-----	0.5ml	9.5ml	2mg/ml	200 mcg GENTAMICIN
MICONAZOLE	10mg/ml ampule -1ml	+ 9ml (NS)	1mg/ml	1ml	9ml	100mcg/ml	10 mcg MICONAZOLE
VANCOMYCIN	250 mg	10ml(NS)	25mg/ml	2ml	3ml	10mg/ml	1000 mcg
METHOD 2	500mg	5ml (NS)/50ml bottle (see overleaf)					

(Note: if INTRATHECAL injectable products are available, these usually do not contain preservatives, and are preferred to products that do contain preservatives. Note that concentrations of these products may be different from products for parenteral injection.)

APPENDIX II PHARMACOKINETICS AND PHARMACODYNAMICS (PK/PD): fundamentals for understanding antibiotic action in the eye

FOREWORD

The science of pharmacokinetics/pharmacodynamics remains a relatively poorly understood, and very underutilized, tool in our quest to deliver effective antibiotic regimens to the eye, be they for treatment or for prevention of infection.

In foregoing sections of these Guidelines, the clear effect of the intracameral injection is made evident by the data, and by growing testimony that initiating an intracameral injection, or adding it to other regimens, results in rather dramatic reductions in postoperative endophthalmitis rates.

In many ways, because results of large clinical trials are required by regulatory agencies to grant endorsement of a clinical treatment, one must often put the cart before the horse. Yet, the underlying principles of science, of fundamental logic, govern how drugs will interact with target organs such as the

eye. Exploration into these fundamentals can save much time and money, and pave the way to further insights that may help our cause. They provide the scientific rationale.

The field is wide open, and begs for this kind of research in Ophthalmology today. We face a time when larger proportions of the population around the world will need cataract surgery, and with regional challenges likely different from our own. To stay ahead of this ever changing dynamic, basic research should guide our thinking.

This Appendix reviews some simple concepts of PK/PD that will hopefully stimulate interest - and confidence - in our ability to piece together scientific realities and adapt them to our needs as we better define prophylaxis regimens that prevent postoperative endophthalmitis.

We include this section on aspects of PK/PD because this topic remains a poorly understood, and poorly explored, area of antibiotic prophylaxis for the eye. The fundamental scientific principles that describe how antibiotic is delivered to tissues or spaces of the eye, and how antibiotic levels impact microbial eradication, is fundamental to the design of any prophylactic regimen for cataract surgery.

It is fair to say that virtually no studies have attempted to duplicate, in a laboratory setting, the real-life clinical circumstances surrounding bacterial contamination of the eye during cataract surgery and to quantitate what is needed in terms of antibiotic delivery in this setting. That is, the PK/PD of antibiotic prophylaxis is undefined. Undoubtedly, there are many variables and, in this void, the ophthalmic surgeon is left to speculate, or assume, that antibiotic regimens chosen empirically are likely to work. In this Appendix, we offer the student of this important topic the basic tools to help interpret the literature and navigate the research.

One fundamental misconception in recent years has been the assumption that simply attaining a specified microbial MIC in aqueous humor, for example, was the end goal, and that bacterial eradication would follow. This underlying assumption drove much research to measure “peak” antibiotic levels after a countless variety of preoperative antibiotic drop regimens. These were important first steps in laying the foundation for understanding limitations of various forms of antibiotic delivery to the eye. Research in recent years, fortunately, has ventured further by describing bacterial time/kill profiles and acknowledging that *time* was often as important a factor as antibiotic concentration for bacterial eradication in the eye.

Pharmacokinetics (PK) is the science that describes the mathematical distribution of drugs within the body; parameters include absorption rates, tissue distribution, peak levels, and elimination rates. “Pharmacodynamics” (PD) describes the pharmacological effect of these drug levels on a target objective. In the case of prophylaxis of infection in the eye, PK/PD describes what drug levels are achieved, and what effect they are likely to exert on bacteria or other microbes. One reason for the limited amount of data in this area is that the eye does not lend itself to multiple samplings and precise animal models are difficult to establish.

Consequently, reports presenting ocular “pharmacokinetics” of antibiotics in the literature are often limited to the simple concepts of peak antibiotic levels, measured at feasible time points. These findings are coupled with a collective understanding of standard laboratory definitions of microbial “susceptibility” or “resistance,” yet these laboratory standards have not been adapted to conditions surrounding the eye. Therefore, much conjecture remains about what really occurs in the eye when antibiotics are administered in traditional fashion.

In these Guidelines, we discuss these basic concepts of PK/PD as they may relate to combating bacteria that contaminate the eye during cataract surgery. With a better understanding of these basic principles, and by utilizing information about antibiotic mechanisms of action, derived even from non-ophthalmic sources, we are better able to construct more logical approaches - and expectations - surrounding prophylaxis of postoperative endophthalmitis. A basic review of this material will shed light on why the intracameral antibiotic injection is likely the preferred route of administration at this point in time, and why the remarkable reductions in postoperative endophthalmitis rates described in these Guidelines are substantiated in great part by the principles of pharmacokinetics and pharmacodynamics.

MICROBIAL ERADICATION WITH TOPICAL ANTIBIOTIC DROPS: COMPARISON OF THE INTRACAMERAL INJECTION WITH PREOPERATIVE TOPICAL DROPS, PK/PD ASPECTS

Because multiple sampling of the human eye is not feasible, and experimental models fall short of our needs, we turn to the few clinical findings available along with anecdotal reports in the literature. The ESCRS study on prophylaxis of endophthalmitis remains the only clinical trial to date that examined the value of the intracameral injection for prophylaxis of endophthalmitis after cataract surgery and included study groups receiving a pulsed perioperative antibiotic drop regimen as well as the intracameral injection.

Results of the ESCRS study offered a comparison of the relative effect of the intracameral injection vs a topical drop regimen; a subsequent study by Sundelin and associates (2009) that replicated the pulsed antibiotic drop regimen of the ESCRS study (Group C) offered insight into the aqueous humor levels that might have been achieved there. ESCRS study Group C proved inferior to the intracameral injection, and the Sundelin study indicated that the highest aqueous humor levofloxacin drops reported to date had likely been achieved, yet were far less effective than the intracameral injection. The discussions below will help to shed light on the principles that support the findings of both these studies.

Antibacterial action in the eye is related to the antibiotic levels achieved at a target site - as well as the duration of effective levels for a period of time. Other factors such as inoculum size, virulence of the microbe, host immune response and wound healing, also play a role, but we focus here on the delivery and anticipated effects of antibiotics given to prevent infection after cataract surgery.

Topical Drops

Prophylactic preoperative antibiotic drops are instilled in the tear film with two basic aims: a) to reduce microbial flora in the precorneal tear film prior to surgery, and b) to allow diffusion of topically applied antibiotic into the anterior chamber with the intention of combating bacteria at that site.

Three distinct periods of time may be described in the antibiotic prophylaxis of cataract surgery: (1) the preoperative time period (where topical drops are intended to reduce or eliminate bacteria on the ocular surface); (2) the intra-operative period (where contamination may occur during the surgical procedure itself); (3) the early postoperative period where wound healing, surface antisepsis and environmental factors may still induce infection.

a) Preoperative Time Period

Topical antibiotic drops are instilled in concentrations much higher than are utilized in standard laboratory procedures that define bacterial susceptibility or resistance. Nevertheless, after instillation in the eye, these concentrations are immediately diluted in the tear film, and undergo swift elimination via nasolacrimal drainage.

Because these instilled antibiotic concentrations are very high compared to common bacterial MICs, the assumption is made that bacteria are killed on the ocular surface after topical antibiotic drops are given. However, this assumption overlooks the important element of time, as bactericidal effects are typically not instantaneous, but require a period of “drug-bug” contact time in order to produce a bactericidal effect.

Studies demonstrate that a surprisingly longer period of “contact time” may be required to kill even the common strains of bacteria implicated in postoperative endophthalmitis.

Figures 1A and B show that, even with in vitro exposure to a full strength commercially available antibiotic drop, time periods as long as one hour or more were required to kill microbes [Callegan 2009, Hyon 2009]. The product that contained benzalkonium chloride (BAK) 0.005% produced more rapid bacterial killing than did the product without benzalkonium chloride. (Note that the high concentrations tested were actually higher than would be realized in the tears because immediate dilution occurs on drop instillation).

These studies highlighted the somewhat surprising finding at the time, that contact time was a crucial element for bacterial killing, even for such high concentrations of antibiotics that were considered “concentration-dependent” agents. These findings suggested that bacterial killing on the ocular surface was not a *fait accompli*

even with the newly available fluoroquinolone antibiotic drops. Considering that these drops represent antibiotic concentrations (0.3% = 3000 µg/ml; 0.5% = 5000 µg/ml) extraordinarily higher than MICs of common ocular microbial strains (often near 1-2 µg/ml), the ability of these agents to “sterilize” the ocular surface now seems less certain, and their ability to eradicate bacteria inside the eye (where antibiotic concentrations are much lower than in tears) even less likely.

In fact, a number of studies have shown that, despite vigorous antibiotic drop dosing schedules, the ocular surface is not readily “sterilized” after use of topical antibiotic drops. Povidone-iodine, as discussed, remains the most reliable, proven form of ocular surface disinfection preoperatively (but should not be used inside the eye due to toxicity).

Figure 1A

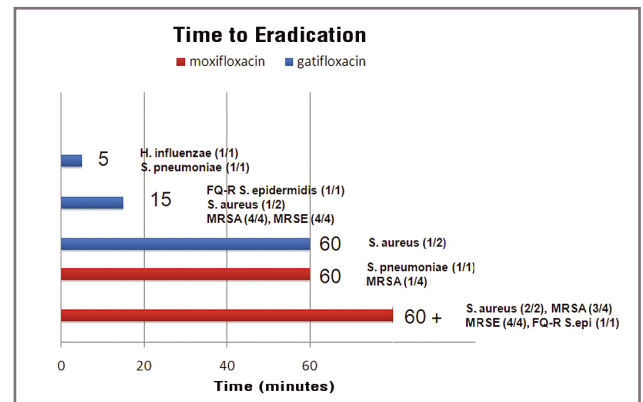


Figure 1B

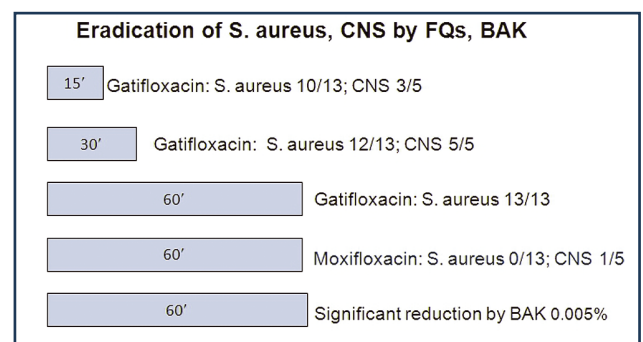


Fig. 1A: adapted from Callegan et al. Adv Ther 2009;26:447. Bacteria were exposed in vitro to gatifloxacin 0.3% or moxifloxacin 0.5% commercially available drops.

Fig 1B: adapted from Hyon et al. J Cat Refract Surg 2009;35:1609.

Table 1. Interpatient variability after topical drops

Large interpatient variability after drops: peak ± SD, range (µg/ml, gm)			
TEARS			
Raizman et al, 2002	levofloxacin	221.06	±256.68
Akkan et al. 1997	ciprofloxacin	11.28	±6.98
	norfloxacin	13.28	±8.78
Granvil et al. 2008	besifloxacin	610	±540
AQUEOUS HUMOR			
Sundelin et al, 2009	levofloxacin	4.4	2.56-7.46
Koch et al. 2006	levofloxacin	1.14	±0.72
McCulley et al. 2006	gatifloxacin	0.94	±0.72
	moxifloxacin	1.86	±1.06
Lai et al. 2007	moxifloxacin	1.58	±0.75
<i>Concentrations reflect measurements taken at various time points</i>			

Tear levels after topical antibiotic drops

Despite the very high antibiotic concentrations delivered to tears by topical antibiotic drops, several factors mitigate against achieving meaningful antibiotic levels inside the eye after drop administration.

Interpatient variability: The first of these is a high interpatient variability in the percentage of an administered drop that is retained in the conjunctival cul-de-sac. Only a very small volume of fluid can be added and retained in the cul-de-sac. Because the volume of commercial drops is so much larger than this small volume, much of an administered drop spills out of the conjunctival cul-de-sac, and is lost. Added to this is the inconsistency in patient self-administered drops, making topical drops an overall poorly efficient, and poorly reliable, drug delivery system. Inter-patient variability in measured tear levels of antibiotics after topical drop administration is depicted in Table 1, where the variability (SD, range) is nearly 100% of measured tear levels. Therefore, the clinician cannot be assured that an intended dose of antibiotic is delivered via topical drops.

Rapid elimination: The second factor that impacts tear levels after topical drop administration is the rapid removal of instilled drops from the tears, due to tear turnover time, and the rapid associated decline in antibiotic tear levels. Freidlander and associates (2006) measured the decline of BAK levels in tears after an antibiotic drop containing 0.005% BAK (equivalent of 50 µg/ml BAK). From an instilled concentration of 50 µg/ml, only 6.4µg /ml BAK remained in tears at 30 seconds after instillation; by 1 minute, levels had declined to 3.2 µg/ml. Thus, from an instilled “concentration” of 50 µg/ml, only approximately 6% was found in tears after only 1 minute of normal tear turnover. While BAK may not represent the decline in tears of every administered agent (some may sequester in adjacent tissues), this study does emphasize the huge loss from tears of any administered agent in topical drop form.

B) Intra-operative Time Period

Aqueous Humor (AH) antibiotic levels after topical drop administration

After topical administration, antibiotic is assumed to penetrate by simple diffusion from the precorneal tear film, through corneal layers, to the anterior chamber (AC). AH levels are reported after a great variety of topical dosing regimens, with AH sampling just prior to incision during cataract surgery and after a specific preoperative dosing regimen had been followed. In this way, the value of increasing or varying preoperative dosing regimens was assessed, with the goal of achieving the highest possible antibiotic levels in AH.

Whenever these measured AH levels exceeded common bacterial MICs, “efficacy” against the microbe was implied. Yet, this assumption might be premature for the following reasons:

- a) Reported AH antibiotic levels rarely exceeded 1-4 µg/ml, no matter how vigorous the preop dosing regimen (Table 2) [Holland 2008, Ong-tone 2007, Katz 2005, Price 2005, McCulley 2006, Solomon 2005, Kim 2005, Hariprasad 2005, Sundelin 2009, and others]. Yet, these low levels will decline even further, in parallel with the rate of AH turnover (approximately 2 hours) so that antibiotic levels, as well as “drug-bug” contact time, are limited, suggesting that bactericidal effects might not occur under these circumstances.
- b) The consistently low antibiotic levels measured in AH after topical drops also exhibit a high degree of interpatient variability; this naturally follows the high interpatient variability seen in tears. The process of diffusion into AH stabilizes this variability to some degree, but variability in the range of approximately 50% in peak AH levels is still evident in Table 1. Again, the clinician cannot be assured that specific antibiotic levels will be achieved in AH following topical antibiotic drop administration.
- c) Last, but not least, is the reality that no matter what antibiotic levels may be achieved in AH due to preoperative drop dosing, these AH levels are drained at the moment of surgical incision, so that the AH levels during surgery, derived from preoperative drops, are essentially zero. (The contribution of any antibiotic sequestration in ocular tissues is minimal to negligible and would not help sustain meaningful aqueous humor levels.)

In summary, reported AH antibiotic levels after topical drop regimens are extremely low compared with levels in tears; they also exhibit high interpatient variability, and their antimicrobial potential is lost because they are drained away at the time of surgical incision.

Table 2. Mean AH levels (mcg/ml) of fluoroquinolones after topical drops

Moxifloxacin 0.5%	Gatifloxacin 0.3%	Levofloxacin 0.5%	1.5%	
		4.430		Sundelin 2009
		1.619		Bucci 2004
	0.0523		0.976	Holland 2007
1.31	0.63			Solomon 2005
1.18	0.48			Kim 2005
1.74				Katz 2005
	1.26			Price 2005
2.28				Hariprasad 2005
1.86				McCulley 2006
2.16	0.82			Ong-Tone 2007
0.9	0.3			Holland 2008

C) Early Postoperative Time Period

Few data exist that specifically address this time period, or the best choice of prophylactic measures for this time period. Some clinicians administer antibiotic drops vigorously in the immediate postoperative period, while others do not. Clinical findings relating to postoperative endophthalmitis rates and perioperative antibiotic drop administration have been presented above in these Guidelines.

After an intracameral injection, intraocular levels of antibiotic do persist in the aqueous humor for a period of time. A study by Sundelin and associates (2009) reproduced the intensive, pulsed drop regimen utilized in the ESCRS study Group C, where (in addition to two preoperative drops), three pulsed fluoroquinolone drops, given 5 minutes apart, were administered at the close of surgery. This regimen produced the highest AH levels of fluoroquinolone reported to date, yet the group receiving the identical regimen in the ESCRS study (Group C) exhibited higher postoperative endophthalmitis than the group receiving intracameral cefuroxime (Group B). No statistical difference was seen between the group receiving topical drops only (Group C), and control (Group A), although some additive effect was noted in Group D (where both intracameral injection and topical drops were given). The recent report from Sweden³ found no additional benefit from perioperative drops added on to intracameral cefuroxime. This is shown in detail earlier in these guidelines (Table 23).

However, the risks associated with cataract surgery imply that the ocular surface itself may be a focus of attention in the immediate postoperative time period. Clinicians must determine if treatments for the ocular surface are warranted, as discussed above.

PK/PD implications of reported AH antibiotic levels after topical drops

Because no laboratory standards duplicate conditions surrounding antibiotic drop administration to the eye, effects on bacteria of antimicrobial interventions currently used are difficult to determine precisely. We must rely on piecing together the science we do know and understand, from various sources, to make logical projections for effects in the eye. These sources include:

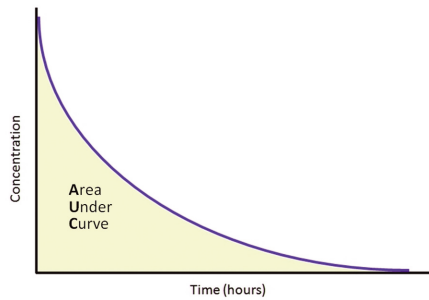
- a) Standard Laboratory Definitions: Standard laboratory definitions of bacterial susceptibility (sensitivity) or resistance are available in most regions of the world. These reflect not only updated data on local bacterial susceptibility, but changing trends in the etiology of ocular infections.
- b) Data from surveillance studies such as the Ocular TRUST (Tracking Resistance in U.S. Today) provide insight into *in vitro* bacterial susceptibility (MICs) of ocular isolates, and trends in bacterial resistance to antibiotics. The clinician is encouraged to remain updated on similar reports in his region. In Europe, the EARS-Net (European Antimicrobial Resistance Surveillance Network), supported by the European Centre for Disease Prevention and Control, maintains a database for overall regional trends in microbial resistance.

Nevertheless, these reports generally utilize standard laboratory definitions for bacterial susceptibility or resistance, where the laboratory exposure times between microbe and antibiotic are longer than the time periods characteristic of clinical settings in ophthalmology.

- c) PK data from the literature: PK Parameters Describing Bacterial Killing/Time Profiles
 - **AUC:** The literature does provide insight into the relationship between microbial killing and the duration of exposure to antibiotic, via pharmacokinetic parameters such as the AUC (area-under-the-curve; also, AUC and others). The AUC measures antibiotic levels over time (much like “man-hours on the job”) (Figure 2) and these have been related to bacterial eradication and/or clinical success in specialties outside of Ophthalmology. While published data stem primarily from observations after systemically administered antibiotics, these offer valuable insights for the ophthalmic clinician.

When the effects of modern antibiotics such as fluoroquinolones (widely used for the treatment of respiratory infections) were analyzed in terms of AUC and bacterial eradication, it became apparent that the ratio of AUC/MIC (ratio of the AUC to the microbial MIC) was an important determinant for successful outcomes [Wispelway 2005], [Zelenitsky 2003]. A number of studies confirmed that an AUC/MIC ratio above approximately 30 (for many Gram-positive strains), and above 100 (for Gram-negative) was needed to eradicate bacteria, and that even higher ratios of AUC/MIC were associated with better outcomes.

Figure 2. Depiction of “Area Under The Curve”



(Units used: $mg \cdot hr/L = mcg \cdot hr/mL$)

- **C_{max}/MIC:** This parameter describes antimicrobial activity in terms of the ratio of the peak antibiotic concentration achieved (C_{max}) to the microbial MIC (C_{max}/MIC), and is particularly applicable to antibiotics considered to be “concentration-dependent” (eg: fluoroquinolones, aminoglycosides).

C_{max}/MIC ratios ≥ 10 are cited as desirable for fluoroquinolone antibiotics [Odenholt, Cars] and are associated with better bacterial eradication. However, this ratio should not be viewed independently of the AUC/MIC that is reliably associated with eradication of bacteria by fluoroquinolone antibiotics.

- **T_{>MIC}:** This PK parameter describes the period of time (in the dosing interval) during which antibiotic levels remain above the microbial MIC; it is associated with antibiotics considered to be “time-dependent” (eg: cephalosporins, macrolides). For these antibiotics, studies indicate a period of time of approximately 50% of the dosing interval, where antibiotic levels are sustained above microbial MIC, produce optimal effects.

A more in-depth discussion of these parameters is beyond the scope of these Guidelines, since additional factors such as host immune response, microbial inoculum, bacterial strain, protein binding and others (not to mention the effects of a single dose vs multiple antibiotic doses) also play a role in determining antimicrobial response. We should bear in mind that the relationship of these PK parameters to successful outcomes in the prevention (or treatment) of ocular infections has not been established because study models are difficult to construct. Nevertheless, an awareness of these basic PK/PD principles will aid the clinician in making broad comparisons between topical drops vs intracameral injection or other routes of administration in real-life clinical settings.

Because giving multiple antibiotic injections into the eye is not an option, and because tear and AH turnover rates remove antibiotic from those sites, the best option is to maximize antibiotic delivery, whenever possible, to eradicate bacteria in the anterior chamber of the eye.

- d) Coordinating what is known about antimicrobial PK/PK and the eye

AUC and AH Antibiotic Levels: Table 3 displays the few reports that measured AUCs of common fluoroquinolones in the AH after preoperative drops. Although AUC is described only for the first few hours after dosing, it is apparent that the high target AUC/MIC ratios cited in the literature (at least 50 - 100), associated with successful clinical outcomes after systemic antibiotic administration, really cannot be achieved in the AH after topical drops.

Figure 3 shows a comparison of the AUC in AH after topical drops vs intracameral injection; the AUC after intracameral injection is approximately 1000-fold higher than after topical drops.

Table 4 summarizes comparisons of various PK parameters in aqueous humor after topical drops vs intracameral injection.

Table 3. Reported AUC in AH after topical drops

AUC ($\mu g/ml$) in AH after topical FQ drops		
Levofloxacin 0-90 min	4.05	Sundelin et al. Acta Ophthalmologica 2009
Moxifloxacin 0-3h	4.41	Katz et al. Cornea 2005
Moxifloxacin Gatifloxacin 0-2h	1.2 0.4	Holland et al. Cornea 2008

Figure 3. Comparison of relative AUC after IC, drops

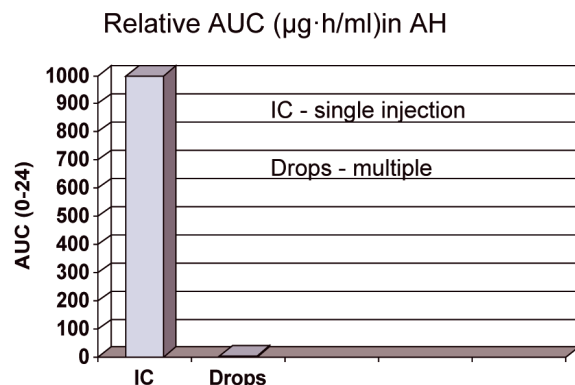


Table 4. Summary of PK comparisons in AH between drops and intracameral injection

Comparative AH levels		
	Drops (levofloxacin)	Intracameral (cefuroxime)
AH peak (Cmax)	4.4 mcg/ml ESCRS dosing ^a	4000 mcg/ml ESCRS study ^b
Cmax/MIC ratio	35.2 - 0.73 (MIC range 0.125 - 6 mcg/ml) ^c	125,000 - 1333 (MIC range 0.032 - 3 mcg/ml) ^c
AUC	4 mg•hr/L ^a (t _{0-1.5h})	4125 mg•hr/L (estimated t _{0-1.5}) ^d
AUC/MIC ratio	32 - 0.6 ^a	688 - 33,000 (estimated t _{0-1.5}) ^d

a. Data from Sundelin et al. 2009, Acta Ophthalmologica 87:160, duplicating ESCRS study Group C dosing.
b. Extrapolated from ESCRS study 2007, J Cat Refract Surg 33:978, using 1mg cefuroxime dose and AH volume of 0.25ml.
c. MIC values obtained from ESCRS study data and Seal D, et al. J Cat Refract Surg 2008; 34:1439-50.
d. Using calculated, estimated AUC, 0-1.5hr from available data.

Results of the ESCRS study confirmed that postoperative endophthalmitis rates in the study group receiving the intracameral injection (Group B) were lower than in the group receiving topical antibiotic drops (Group C). This finding is even more meaningful considering that, in the ESCRS study, Group C received a pulsed dose drop regimen of a fluoroquinolone at the conclusion of surgery (as opposed to preoperative drops only), allowing a more direct comparison of topical drops vs intracameral injection.

Intracameral injection vs subconjunctival injection

Subconjunctival injection is expected to deliver lower antibiotic levels to the anterior chamber (AC) than an intracameral injection, because subconjunctival injection requires drug diffusion to the AC. Jenkins and associates (1996) measured cefuroxime levels after subconjunctival injection of 125 mg cefuroxime; mean peak AH levels (12-24 minutes after dose) were 20.33 µg/ml. In comparison, an intracameral injection of 1mg cefuroxime would be expected to deliver approximately 3300 µg/ml cefuroxime to the anterior chamber (assuming 0.3ml AC volume) - at least 100-fold more.

One centre described a 3-fold reduction in postoperative endophthalmitis rates after the practice of injecting 50mg subconjunctival cefuroxime was discontinued and replaced with intracameral injection of 1mg cefuroxime at the end of cataract surgery [Yu-Wai-Man 2008]. The associated patient discomfort is an additional drawback of the subconjunctival injection.

Nevertheless, many centres utilize subconjunctival injections, as these may deliver higher levels of antibiotic to the AC than drops. Jenkins and associates reported that topical cefuroxime 50 mg/ml drops produced AH levels of

0.18 - 2.16 µg/ml; in contrast, subconjunctival injection of 25 mg cefuroxime produced peak AH levels of 2.31-5.65 µg/ml.

Irrigating Solutions

Irrigating solutions deliver a flow of antibiotic at a constant concentration. However, these antibiotic concentrations are considerably lower than concentrations delivered by intracameral injection; there is also no means of quantitating the total exposure to antibiotic after irrigation. The additional factor of time of exposure to antibiotic also mitigates against the usefulness of these irrigating solutions. *In vitro* antimicrobial activity of vancomycin is observed after approximately 3-4 hours, with full activity exhibited in about 24 hours [Kowalski 1998, Caillon 1989, Gritz 1996, Keverline 2002].

One study found a 5% AC contamination rate in patients treated with an irrigating solution containing vancomycin plus gentamicin, vs a rate of 12% in the placebo-treated group [Ferro 1997], which suggests that AC contamination may persist despite use of irrigating solutions. Some reports have described a reduction in contamination rates after irrigating solution [Mendivil 2001, Beigi 1998], but failure to detect a difference in contamination rate is also reported after use of a vancomycin irrigating solution [Feys 1997]. One study reports that 90% (9/10) of the Gram-positive isolates in cases of endophthalmitis in a large retrospective series were sensitive to cefuroxime, whereas all (10/10) were resistant to gentamicin and 50% (4/8) were resistant to the fluoroquinolones tested. All (3/3) of the Gram-negative isolates were susceptible to cefuroxime, gentamicin and the fluoroquinolones [Ness 2011]. During the period of the study gentamicin irrigation had been used, but no intracameral antibiotics.

The fundamental principles remains that a) the antibiotic concentrations used in irrigating solutions are much lower than the intracameral injection and b) there is essentially no continuous “drug-bug” contact time between antibiotic and microbe with use of irrigating solutions, except for the low concentration of the irrigation that remain behind.

We should also not overlook the issue of potential retinal toxicity with profuse irrigation with certain antibiotics (particularly aminoglycosides), as well the risk of encouraging bacterial resistance through open exposure to the antibiotic in the surgical field. There seems to be no real advantage to use of irrigating solutions over the use of an intracameral injection.

Specifically, the use antibiotics in irrigating solutions is discouraged by organisations such as the Centers for Disease Control (1995), the American Academy of Ophthalmology (AAO-CDC 1999) and also by clinicians (May 2000). For these several reasons, and because the usefulness of antibiotics in irrigating solutions has not been proven, this means of prophylaxis is not recommended in these Guidelines.

REFERENCES AND BIBLIOGRAPHY

KEY REFERENCES

1. Endophthalmitis Study Group, European Society of Cataract & Refractive Surgeons. Prophylaxis of postoperative endophthalmitis following cataract surgery: results of the ESCRS multicenter study and identification of risk factors. *J Cataract Refract Surg* 2007; 33: 978-88
2. Shorstein NH, Winthrop KL, Herrinton LJ. Decreased postoperative endophthalmitis rate after institution of intracameral antibiotics in a Northern California eye department. *J Cataract Refract Surg* 2013; 39:8-14
3. Friling E, Lundström M, Stenevi U, Montan P. Six-year incidence of endophthalmitis after cataract surgery: Swedish national study. *J Cataract Refract Surg* 2013; 39: 15-21
4. Seal D, Reischl U, Behr A et al; ESCRS Endophthalmitis Study Group. Laboratory diagnosis of endophthalmitis: comparison of microbiology and molecular methods in the European Society of Cataract & Refractive Surgeons multicenter study and susceptibility testing. *J Cataract Refract Surg* 2008; 34: 1439-1450
5. Lundström M, Wejde G, Stenevi U, et al. Endophthalmitis after cataract surgery: a nationwide prospective study evaluating incidence in relation to incision type and location. *Ophthalmology* 2007;114:866-70
6. Barreau G, Mounier M, Marin B, Adenis JP, Robert PY. Intracameral cefuroxime injection at the end of cataract surgery to reduce the incidence of endophthalmitis: French study. *J Cataract Refract Surg* 2012; 38: 1370-5
7. Van der Merwe J, Mustak H, Cook C. Endophthalmitis prophylaxis with intracameral cefuroxime in South Africa. *J Cataract Refract Surg* 2012; 38: 2054
8. García-Saenz MC, Arias-Puente A, Rodríguez-Caravaca G, et al. Effectiveness of intracameral cefuroxime in preventing endophthalmitis after cataract surgery: Ten year comparative study. *J Cataract Refract Surg* 2010;36:203-207
9. Rodríguez-Caravaca G, García-Sáenz MC, Villar-del-Campo MA, et al. Incidence of endophthalmitis and impact of prophylaxis with cefuroxime on cataract surgery. *J Cataract Refract Surg* 2013;39:1399 - 1403
10. Endophthalmitis Vitrectomy Study Group. Results of the Endophthalmitis Vitrectomy Study. A randomized trial of immediate vitrectomy and of intravenous antibiotics for the treatment of postoperative bacterial endophthalmitis. *Arch Ophthalmol* 1995; 113: 1479-1496
11. Barry P, Gardner S, Seal D et al; ESCRS Endophthalmitis Study Group. Clinical observations associated with proven and unproven cases in the ESCRS study of prophylaxis of postoperative endophthalmitis after cataract surgery. *J Cataract Refract Surg* 2009; 35: 1523-31
12. Montan PG, Wejde G, Koranyi G, Rylander M. Prophylactic intracameral cefuroxime: Efficacy in preventing endophthalmitis after cataract surgery. *J Cataract Refract Surg*. 2002;28: 977-981
13. Montan PG, Wejde G, Setterquist H, et al. Prophylactic intracameral cefuroxime; evaluation of safety and kinetics in cataract surgery. *J Cataract Refract Surg* 2002;28:982-987
14. Barry P. Adoption of intracameral antibiotic prophylaxis of endophthalmitis following cataract surgery. *J Cataract Refract Surg*, in press.

BIBLIOGRAPHY

- AAO-CDC Task Force: The prophylactic use of vancomycin for intraocular surgery. Quality of Care Publications, Number 515, American Academy of Ophthalmology, San Francisco, CA, October 1999
- Aguilar HE, Meredith TA, Drews C, Grossniklaus H, Sawant AD, Gardner S. Comparative treatment of experimental *Staphylococcus aureus* endophthalmitis. *Am J Ophthalmol* 1996;121:310-7
- Albrecht E, Richards JC, Pollock T et al. Adjunctive use of intravitreal dexamethasone in presumed bacterial endophthalmitis: a randomised trial. *Br J Ophthalmol* 2011; 95:1385-8
- Alcon Laboratories. Product Information 5.1 Warnings and Precautions. Available at: http://ecatalog.alcon.com/PI/Vigamox_us_en.pdf. Accessed August 12, 2013
- Aldave AJ, Stein JD, Deramo VA et al. Treatment strategies for postoperative *Propionibacterium acnes* endophthalmitis. *Ophthalmology* 1999; 106: 2395-401
- Alemán AM, Quirce S, Cuesta J, Novalbos A, Sastre J. Anaphylactoid reaction caused by moxifloxacin. *J Invest Allergol Clin Immunol* 2002;12:67-8
- American Academy of Ophthalmology. *Cataract in the Adult Eye; Preferred Practice Patterns*. San Francisco, CA, American Academy of Ophthalmology, 2011. Available at: http://one.aao.org/CE/PracticeGuidelines/PPP_Content. Accessed August 12, 2013
- Anand AR, Therese KL, Madhavan HN. Spectrum of aetiological agents of postoperative endophthalmitis and antibiotic susceptibility of bacterial isolates. *Indian J Ophthalmol* 2000; 48: 123-8.
- Anderson RL, Vess RW, Carr JH, et al. Investigations of intrinsic *Pseudomonas cepacia* contamination in commercially manufactured povidone-iodine. *Infect Control Hosp Epidemiol*. 1991 May;12(5):297-302
- www.medicines.org.uk/emc/printfriendlydocument.
- Apt L, Isenberg S, Yoshimori R, et al. Chemical preparation of the eye in ophthalmic surgery. III: effect of povidone-iodine on the conjunctiva. *Arch Ophthalmol* 1984;102:728-729
- Arbisser LB. Safety of intracameral moxifloxacin for prophylaxis of endophthalmitis after cataract surgery. *J Cataract Refract Surg*. 2008 Jul;34(7):1114-20.
- Baillif S, Roure-Sobas C, Le-Duff F, Kodjikian L. Aqueous humor contamination during phacoemulsification in a university teaching hospital. *J Fr Ophthalmol*. 2012 Mar;35(3):153-6.
- Bannerman TL, Rhoden DL, McAllister SK, et al. The source of coagulase-negative staphylococci in the Endophthalmitis Vitrectomy Study. A comparison of eyelid and intraocular isolates using pulsed-field gel electrophoresis. *Arch Ophthalmol* 1997;115:357-61
- Barry P, Behrens-Baumann W, Pleyer U, Seal D, 2007 2nd Edition ESCRS Guidelines on prevention, investigation and management of post-operative endophthalmitis. www.escrs.org
- Barry P, Seal D, V., Gettinby, G., Lees, F., Peterson, M., Revie, C. W.: ESCRS study of prophylaxis of post-operative endophthalmitis after cataract surgery: Preliminary report of principal results from a European multi-centre study. *J Cataract Refract Surg*. 32, 2006, 407 – 410
- Barza M, Pavan PR, Doft BH et al. Evaluation of microbiological diagnostic techniques in postoperative endophthalmitis in the Endophthalmitis Vitrectomy Study. *Arch Ophthalmol* 1997; 115: 1142-1150
- Behndig A, Cochener B, Güell JL, et al. Endophthalmitis prophylaxis in cataract surgery: Overview of current practice patterns in 9 European countries. *J Cataract Refract Surg*. 2013 Sep;39(9):1421-1431.
- Behndig A, Montan P, Stenevi U et al. One million cataract surgeries: Swedish Cataract Registry 1992-2009. *J Cataract Refract Surg* 2011;37:1539-45.

- Beigi, B., Westlake, W., Chang, B., Marsh, C., Jacob, J., Riordan, T.: The effect of intracameral, per-operative antibiotics on microbial contamination of anterior chamber aspirates during phacoemulsification. *Eye* 12, 1998, 390 - 394
- Behrens-Baumann, W.: *Mycosis of the Eye and its Adnexa*. In: *Developments in Ophthalmology* 32, S. Karger AG, Basel 1999 (with a contribution by R. Röchel)
- Bispo PJ, de Melo GB, Hofling-Lima AL, Pignatari AC. Detection and gram discrimination of bacterial pathogens from aqueous and vitreous humor using real-time PCR assays. *Invest Ophthalmol Vis Sci* 2011; 52: 873- 881
- Bodnar Z, Clouser S, Mamalis N. Toxic anterior segment syndrome: Update on the most common causes. *J Cataract Refract Surg* 2012; 38: 1902-10
- Bucci FA Jr, Amico LM, Evans RE. Antimicrobial efficacy of prophylactic gatifloxacin 0.3% and moxifloxacin 0.5% in patients undergoing phacoemulsification surgery. *Eye Contact Lens* 2008;34:39-42
- Caillon, J., Juvin, M. E., Pirault, J. L., Drugeon, H. B.: Activité bactéricide de la Daptomycine (LY 146032) comparée à celle de la Vancomycine et de la Teicoplanine sur les bactéries à gram positif. *Path Biol* 37, 1989, 540 - 548
- Cakir M, Imamoglu S, Cekic O, et al. An outbreak of early-onset endophthalmitis caused by *Fusarium* species following cataract surgery *Curr Eye Res* 2009;34:988-95
- Callegan MC, Novosad BD, Ramadan RT, et al. Rate of bacterial eradication by ophthalmic solutions of fourth-generation fluoroquinolones. *Adv Ther* 2009;26:447-454.
- Campagna JD, Bond MC, Schabelman E, et al. The use of cephalosporins in penicillin-allergic patients: a literature review. *J Emerg Med* 2012;45: 612-620
- Campagna JD, Bond MC, Schabelman E, Hayes BD. The use of cephalosporins in penicillin-allergic patients: a literature review. *J Emerg Med*. 2012 May;42(5):612-20
- Carrim ZI, Mackie G, Gallacher G, Wykes WN. The efficacy of 5% povidone-iodine for 3 minutes prior to cataract surgery. *Eur J Ophthalmol*. 2009 Jul-Aug;19(4):560-4.
- Centers for Disease Control. Persons with Meningitis Linked to Epidural Steroid Injections by State. Available at:<http://www.cdc.gov/hai/outbreaks/meningitis-map.html>. Accessed August 12, 2013
- Center for Disease Control: Recommendations for preventing the spread of vancomycin resistance. *Morb Mort Wkly Rep* 44 (RR-12), 1995, 1 - 13
- Chang DF, Braga-Mele R, Mamalis N, et al. Prophylaxis of postoperative endophthalmitis after cataract surgery; results of the 2007 ASCRS member survey; the ASCRS Cataract Clinical Committee. *J Cataract Refract Surg*. 2007; 33:1801-1805
- Chang B, Knowles SR, Weber E. Immediate hypersensitivity to moxifloxacin with tolerance to ciprofloxacin: report of three cases and review of the literature. *Ann Pharmacother* 2010;44:740-5
- Ciulla TA, Starr MB, Masket S. Bacterial endophthalmitis prophylaxis for cataract surgery: an evidence-based update. *Ophthalmology* 109, 2002, 13 - 24
- Clark WL, Kaiser PK, Flynn HW Jr et al. Treatment strategies and visual acuity outcomes in chronic postoperative *Propionibacterium acnes* endophthalmitis. *Ophthalmology* 1999; 106: 1665-70.
- Cordoves, L., Abreu, A., Seal, D., Barry, P.: Intravitreal antibiotics: The emergency kit. *J Cataract Refract Surg* 27, 2001, 971 - 972
- Das T, Jalali S, Gothwal VK, Sharma S, Naduvilath TJ. Intravitreal dexamethasone in exogenous bacterial endophthalmitis: results of a prospective randomised study. *Br J Ophthalmol* 1999;83:1050 -1055
- Deramo VA, Lai JC, Fastenberg DM, Udell IJ. Acute endophthalmitis in eyes treated prophylactically with gatifloxacin and moxifloxacin. *Am J Ophthalmol* 2006;142: 721-5.
- Deramo VA, Ting TD. Treatment of *Propionibacterium acnes* endophthalmitis. *Cur Opin Ophthalmol* 2001;12: 225-9
- Derek Y. Kunimoto, DY, Das T, Sharma S, et al. Microbiologic Spectrum and Susceptibility of Isolates: Part I. Postoperative Endophthalmitis. Endophthalmitis Research Group. *Am J Ophthalmol* 1999; 128: 240-2
- Dubey R, Brettell DJ, Montfort J, et al. Obviating endophthalmitis after cataract surgery: excellent wound closure is the key. *Arch Ophthalmol* 2011;129:1504-5
- Doft BM, Kelsey SF, Wisniewski SR. Retinal detachment in the endophthalmitis vitrectomy study. *Arch Ophthalmol* 2000; 118:1661-1665
- Duerden B. MRSA: why have we got it and can we do anything about it? *Eye* 2012;26; 218-221
- Espiritu CR, Caparas VL, Bolinao JG. Safety of prophylactic intracameral moxifloxacin 0.5% ophthalmic solution in cataract surgery patients. *J Cataract Refract Surg*. 2007 Jan;33(1):63-8.
- Ferguson AW, Scott JA, McGavigan J, et al. Comparison of 5% povidone-iodine solution against 1% povidone-iodine solution in preoperative cataract surgery antisepsis: a prospective randomised double blind study. *Br J Ophthalmol*. 2003 Feb;87(2):163-7
- Ferro JF, de-Pablos M, Logrono MJ et al. Postoperative contamination after using vancomycin and gentamicin during phacoemulsification. *Arch Ophthalmol* 1997;155:165-70
- Feys, J., Salvanet-Bouccara, A., Emond, J. Ph., Dublanchet, A.: Vancomycin prophylaxis and intraocular contamination during cataract surgery. *J Cataract Refract Surg* 23, 1997, 894 - 897
- Ficker LA, Meredith TA, Gardner SK, Wilson LA. Cefazolin levels after intravitreal injection: Effects of inflammation and surgery. *Invest Ophthalmol Vis Sci*. 1990;31:502-505
- Freidlander MH, Breshears D, Amoozgar B et al. The dilution of benzalkonium chloride (BAK) in the tear film. *Advances in Therapy* 2006;23:835-841
- Gan IM, Ugahary LC, van Dissel JT, et al. Intravitreal dexamethasone as adjuvant in the treatment of postoperative endophthalmitis: a prospective randomized trial. *Graefes Arch Clin Exp Ophthalmol* 2005;243:1200 -1205
- Garat M, Moser CL, Martín-Baranera M, Alonso-Tarrés C, Alvarez-Rubio L. Prophylactic intracameral cefazolin after cataract surgery: endophthalmitis risk reduction and safety results in a 6-year study. *J Cataract Refract Surg* 2009; 35: 637-42.
- Garat M, Moser CL, Alonso-Tarrés C, Martín-Baranera M, Alberdi A. Intracameral cefazolin to prevent endophthalmitis in cataract surgery: 3-year retrospective study. *J Cataract Refract Surg* 2005; 31: 2230-4.
- Gardner SK. Ocular Drug Penetration and Pharmacokinetic Principles. In: Lamberts DW, Potter DE, eds. *Clinical Ophthalmic Pharmacology*. Boston: Little Brown & Co; 1987:1-52.
- Glasser DB, Gardner SK, Ellis JG, Pettit TH. Loading doses and extended dosing intervals in topical gentamicin therapy. *Am J Ophthalmol*. 1985;99:329-332
- Goel S, Kolli LR, Desai SP, et al. Povidone iodine causes opacification of silicone intraocular lens implants. *Acta Ophthalmol*. 2008 Nov;86:773-7
- Goldberg RA, Flynn HW Jr, Isom RF, et al. An outbreak of streptococcus endophthalmitis after intravitreal injection of bevacizumab. *Am J Ophthalmol*. 2012 153(2):204-208
- Goldschmidt P, Degorge S, Benallaoua D et al. New test for the diagnosis of bacterial endophthalmitis. *Br J Ophthalmol* 2009; 93: 1089-1095
- Gore DM, Angunaweda RE, Little BC, United Kingdom survey of antibiotic prophylaxis practice after publication of the ESCRS Endophthalmitis Study. *J Cataract Refract Surg* 2009; 35:770-773
- Gower EW, Lindsley K, Nanji AA, et al. Perioperative antibiotics for prevention of acute endophthalmitis after cataract surgery. *Cochrane Database Syst Rev*. 2013 Jul 15;7
- Gritz, D. C., Cevallos, A. V., Smolin, G., Whitcher, J. P. Jr.: Antibiotic supplementation of intraocular irrigating solutions. *Ophthalmology* 103, 1996, 1204 - 1209
- Gualino V, San S, Guillot E, et al. Intracameral cefuroxime injections in prophylaxis of postoperative endophthalmitis after cataract surgery: implementation and results. *J Fr Ophtalmol* 2010;33:551-5
- Halachmi-Eyal O, Lang Y, Keness Y, Miron D. Preoperative topical moxifloxacin 0.5% and povidone-iodine 5.0% versus povidone-iodine 5.0% alone to reduce bacterial colonization in the conjunctival sac. *J Cataract Refract Surg*. 2009 Dec;35(12):2109-14

- Hall EF, Scott GR, Musch DC, Zacks DN. Adjunctive intravitreal dexamethasone in the treatment of acute endophthalmitis following cataract surgery. *Clin Ophthalmol*. 2008; 2: 139-45
- Han DP, Wisniewski SR, Kelsey SF et al. Microbiologic yields and complication rates of vitreous needle aspiration versus mechanized vitreous biopsy in the Endophthalmitis Vitrectomy Study. *Retina* 1999; 19:98-102
- Han DP, Wisniewski SR, Wilson LA et al. Spectrum and susceptibilities of microbiologic isolates in the Endophthalmitis Vitrectomy Study. *Am J Ophthalmol* 1996; 122: 1-17
- He L, Ta CN, Hu N, et al. Prospective randomized comparison of 1-day and 3-day application of topical 0.5% moxifloxacin in eliminating preoperative conjunctival bacteria. *J Ocul Pharmacol Ther* 2009;25:373-8
- Healy, D. P., Holland, E. J., Nordlund, M. L., Dunn, S., Chow, C., Lindstrom, R. L., Hardten, D., Davis, E.: Concentrations of levofloxacin, ofloxacin and ciprofloxacin in human corneal stromal tissue and aqueous humor after topical administration. *Cornea* 23, 2004, 255 – 263
- Hegazy HM, Kivilcim M, Peyman GA et al. Evaluation of toxicity of intravitreal ceftazidime, vancomycin, and ganciclovir in a silicone oil-filled eye. *Retina*. 1999; 19: 553-7.
- Hellinger WC, Bacalis LP, Edelhauser HF et al; ASCRS Ad Hoc Task Force on Cleaning and Sterilization of Intraocular Instruments. Recommended practices for cleaning and sterilizing intraocular surgical instruments. *J Cataract Refract Surg*. 2007; 33: 1095-100
- Hosseini H, Ashraf MJ, Saleh M, et al. Effect of povidone-iodine concentration and exposure time on bacteria isolated from endophthalmitis cases. *J Cataract Refract Surg*. 2012;38:92-6
- Hsiao CH, Chuang CC, Tan HY, et al. Methicillin-resistant *Staphylococcus aureus* ocular infection: a 10-year hospital-based study. *Ophthalmology*. 2012;119:522-7
- Hsu HY, Lind JT, Tseng L, Miller D. Ocular flora and their antibiotic resistance patterns in the midwest: a prospective study of patients undergoing cataract surgery. *Am J Ophthalmol*. 2013;155:36-44
- Hykin PG, Tobal K, McIntyre G, Matheson MM, Towler HM, Lightman SL. The diagnosis of delayed post-operative endophthalmitis by polymerase chain reaction of bacterial DNA in vitreous samples. *J Med Microbiol* 1994;40(6):408-415
- Hyon JU, Eser I, O'Brien TP. Kill rates of preserved and preservative-free topical 8-methoxy fluoroquinolones against various strains of *Staphylococcus*. *J Cat Refract Surg* 2009;35:1609-1613
- Idsoe O, Guthe T, Willcox RR, deWeck AL. Nature and extent of penicillin side-reactions, with particular reference to fatalities from anaphylactic shock. *Bull World Health Organ* 1968;38:159-88
- Jambulingam M, Parameswaran SK, Lysa S, et al. A study on the incidence, microbiological analysis and investigations on the source of infection of postoperative infectious endophthalmitis in a tertiary care ophthalmic hospital: an 8-year study. *Indian J Ophthalmol* 2010; 58: 297-302
- Jenkins CDG, Tuft SJ, Sheridah G, et al. Comparative intraocular penetration of topical and injected cefuroxime. *Br J Ophthalmol* 1996;80:685-688
- Jensen, MK, Fiscella, RG, Crandall, AS, et al. A retrospective study of endophthalmitis rates comparing quinolone antibiotics. *Am J Ophthalmol* 139, 2005, 141 – 148
- Johnson MW, Doft BH, Kelsey SF. The Endophthalmitis Vitrectomy Study. Relationship between clinical presentation and microbiologic spectrum. *Ophthalmology* 1997; 104: 261-272
- Joondeph BC, Flynn HW Jr, Miller D, Joondeph HC. A new culture method for infectious endophthalmitis. *Arch Ophthalmol* 1989;107:1334-7
- Karacnji T, Dubey R, Yassine Z, et al. Bacterial-sized particle ingress promoted by suturing: is this true in the real world? *J Cataract Refract Surg* 2011 Dec;37:2235-6; author reply 2236-2237
- Karia N, Aylward GW. Postoperative propionibacterium acnes endophthalmitis. *Ophthalmology* 2001;108:634-5
- Kaynak S, Oner FH, Koçak N, Cingil G. Surgical management of postoperative endophthalmitis: comparison of 2 techniques. *J Cataract Refract Surg* 2003;29: 966-9
- Kelkar PS, Li JT. Cephalosporin allergy. *N Engl J Med* 2001;345:804-9
- Keveline, M. R., Kowalski, R. P., Dhaliwal, D. K.: in vitro comparison of ciprofloxacin, ofloxacin, and povidone-iodine for surgical prophylaxis. *J Cataract Refract Surg* 28, 2002, 915 - 916
- Kowalski, R. P., Karenchak, L. M., Warren, B. B., Eller, A. W.: Time-kill profiles of *Enterococcus* to antibiotics used for intravitreal therapy. *Ophthalmic Surg Lasers* 29, 1998, 295 - 299
- Kratz A, Levy J, Belfair N et al. Broth Culture Yield vs Traditional Approach in the Work-up of Endophthalmitis. *Am J Ophthalmol* 2006; 141:1022-1026
- Kuhn F, Gini G. Vitrectomy for endophthalmitis. *Ophthalmology* 2006; 113: 714
- Kuhn F, Gini G. Ten years after... are findings of the Endophthalmitis Vitrectomy Study still relevant today? *Graefes Arch Clin Exp Ophthalmol* 2005; 243: 1197-9
- Kunimoto DY, Das T, Sharma S et al. Microbiologic spectrum and susceptibility of isolates: part I. Postoperative endophthalmitis. Endophthalmitis Research Group. *Am J Ophthalmol* 1999; 128: 240-2.
- Lalwani GA, Flynn HW Jr, Scott IU et al. Acute-onset endophthalmitis after clear corneal cataract surgery (1996-2005). Clinical features, causative organisms, and visual acuity outcomes. *Ophthalmology* 2008; 115: 473-476
- Lane SS, Osher RH, Masket S, Belani S. Evaluation of the safety of prophylactic intracameral moxifloxacin in cataract surgery. *J Cataract Refract Surg*. 2008 Sep;34(9):1451-9.
- LeBoyer RM, Werner L, Snyder ME, Mamalis N, Riemann CD, Augsberger JJ. Acute haptic-induced ciliary sulcus irritation associated with single-piece AcrySof intraocular lenses. *J Cataract Refract Surg*. 2005; 31: 1421-7
- Leaming D. Comparisons of 2010 ESCRS and ASCRS practice style survey of members. Presented at XXIX Congress of ESCRS. www.esrcs.org
- Li B, Nentwich MM, Hoffmann LE, Haritoglou C, et al. Comparison of the efficacy of povidone-iodine 1.0%, 5.0%, and 10.0% irrigation combined with topical levofloxacin 0.3% as preoperative prophylaxis in cataract surgery. *J Cataract Refract Surg*. 2013;39:994-1001
- Lobera T, Audicana MT, Alarcón E, et al. Allergy to quinolones: Low cross-reactivity to levofloxacin. *J Invest Allergol Clin Immunol* 2010;20:607-611
- Lohmann CP, Heeb M, Linde HJ, Gabel VP, Reischl U. Diagnosis of infectious endophthalmitis after cataract surgery by polymerase chain reaction. *J Cataract Refract Surg* 1998; 24: 821- 826
- Lohmann CP, Linde HJ, Reischl U. Improved detection of microorganisms by polymerase chain reaction in delayed endophthalmitis after cataract surgery. *Ophthalmology*. 2000; 107: 1047-51
- Lundström M. Endophthalmitis and incision construction. *Curr Opin Ophthalmol* 2006; 17: 68-71
- Major JC, Engelbert M, Flynn HW Jr, et al. *Staphylococcus aureus* endophthalmitis: antibiotic susceptibilities, methicillin resistance, and clinical outcomes. *Am J Ophthalmol* 2010;149:278-283
- Mamalis N, Edelhauser HF, Dawson DG et al. Toxic anterior segment syndrome. *J Cataract Refract Surg* 2006; 32: 324-33
- Martin DF, Ficker LA, Aguilar HA, Gardner SK, et al. Vitreous cefazolin levels after intravenous injection: Effects of inflammation, repeated antibiotic doses, and surgery. *Arch Ophthalmol* 1990;108:411-414
- Masket, S.: Is there a relationship between clear corneal cataract incisions and endophthalmitis? *J Cataract Refract Surg* 2005; 31: 643 – 645
- May WN, Castro-Combs J, Kashiwabuchi RT et al. Sutured clear corneal incision: wound apposition and permeability to bacterial-sized particles. *Cornea*. 2013; 32: 319-25
- May, L., Navarro, V. B., Gottsch, J. D.: First do no harm: Routine use of aminoglycosides in the operating room. *Insight* 25, 2000, 77 - 80
- Meisler DM, Palestine AG, Vastine DW et al. Chronic Propionibacterium endophthalmitis after extracapsular cataract extraction and intraocular lens implantation. *Am J Ophthalmol*. 1986; 102: 733-9

- Mendivil Soto, A., Mendivil, M. P.: The effect of topical povidone-iodine, intraocular vancomycin, or both on aqueous humor cultures at the time of cataract surgery. *Am J Ophthalmol* 131, 2001, 293 - 300
- Menikoff, J A, Speaker M G, Marmor M, Raskin E M: A case-control study of risk factors for post-operative endophthalmitis. *Ophthalmology* 98; 1991: 1761 - 1768
- Miller D, Flynn PM, Scott IU, et al. In vitro fluoroquinolone resistance in staphylococcal endophthalmitis isolates. *Arch Ophthalmol* 2006; 124:479-483
- Mino de Kaspar H, Chang RT, Singh K, et al. Prospective randomized comparison of 2 different methods of 5% povidone-iodine applications for anterior segment intraocular surgery. *Arch Ophthalmol* 2005;123:161-5
- Miño de Kaspar H, Chang RT, Singh, et al. Prospective randomized comparison of 2 different methods of 5 % povidone-iodine applications for anterior segment intraocular surgery. *Arch Ophthalmol* 123, 2005, 161 - 165
- Miño de Kaspar H, Shriver EM, Nguyen EV et al. Risk factors for antibiotic-resistant conjunctival bacterial flora in patients undergoing intraocular surgery. *Graefes Arch Clin Exp Ophthalmol* 2003; 241: 730-3
- Miño de Kaspar H, Neubauer AS, Molnar A et al. Rapid direct antibiotic susceptibility testing in endophthalmitis. *Ophthalmology* 2002; 109: 687 - 693
- Moisseev E, Levinger E. Anaphylactic reaction following intracameral cefuroxime injection during cataract surgery. *J Cataract Refract Surg.* 2013; 39:1432-1434
- Mollan SP, Gao A, Lockwood A, Durrani OM, Butler L. Postcataract endophthalmitis: incidence and microbial isolates in a United Kingdom region from 1996 through 2004. *J Cataract Refract Surg* 2007; 33: 265-8.
- Montan, P. G., Setterquist, H., Marcusson, E., et al.: Pre-operative gentamicin eye drops and chlorhexidine solution in cataract surgery. Experimental and clinical results. *Eur J Ophthalmol* 10, 2000, 286 - 292
- Morrissey I, Burnett R, Viljoen L, et al. Surveillance of the susceptibility of ocular bacterial pathogens to the fluoroquinolone gatifloxacin and other antimicrobials in Europe during 2001/2002. *J Infect* 2004;49: 109-14
- Moss JM, Sanislo SR, Ta CN. A prospective randomized evaluation of topical gatifloxacin on conjunctival flora in patients undergoing intravitreal injections. *Ophthalmology* 2009; 116: 1498-501
- Nagaki Y, Hayasaka S, Kodoi C, et al. Bacterial endophthalmitis after small-incision cataract surgery: effect of incision placement and intraocular lens type. *J Cataract Refract Surg* 2003; 29:20-26
- Nentwich MM, Rajab M, Ta CN, et al. Application of 10% povidone iodine reduces conjunctival bacterial contamination rate in patients undergoing cataract surgery. *Eur J Ophthalmol.* 2012 Jul-Aug;22(4):541-6.
- Ness T, Kern WV, Frank U, Reinhard T. Postoperative nosocomial endophthalmitis: is perioperative antibiotic prophylaxis advisable? A single centre's experience. *J Hosp Infect* 2011;78:138-142
- Novalbos A, Sastre J, Cuesta J, et al. Lack of allergic cross-reactivity to cephalosporins among patients allergic to penicillins. *Clin Exp Allergy* 2001;31:438-43.
- Novosad BD, Callegan MC. Severe bacterial endophthalmitis: towards improving clinical outcomes. *Expert Rev Ophthalmol* 2010;5: 689-698
- O'Brien TP, Arshinoff SA, Mah FS. Perspectives on antibiotics for postoperative endophthalmitis prophylaxis: potential role of moxifloxacin. *J Cataract Refract Surg.* 2007 Oct;33(10):1790-800.
- Odenholt I, Cars O. Pharmacodynamics of moxifloxacin and levofloxacin against *Streptococcus pneumoniae*, *Staphylococcus aureus*, *Klebsiella pneumoniae* and *Escherichia coli*: simulation of human plasma concentrations after intravenous dosage in an in vitro kinetic model. *J Antimicrob Chemother* 2006; 58: 960-5
- Ogawa M, Sugita S, Shimizu N et al. Broad-range real-time PCR assay for detection of bacterial DNA in ocular samples from infectious endophthalmitis. *Jpn J Ophthalmol* 2012; 56: 529-35
- Olavi P. Ocular toxicity in cataract surgery because of inaccurate preparation and erroneous use of 50 mg/mL intramural cefuroxime. *Acta Ophthalmol.* 2012; 90(2):e153-154
- Oum BS, D'Amico DJ, Kwak HW et al. Intravitreal antibiotic therapy with vancomycin and aminoglycoside: examination of the retinal toxicity of repetitive injections after vitreous and lens surgery. *Graefes Arch Clin Exp Ophthalmol.* 1992; 230: 56-61
- Ozdam PC, Mansour M, Deschênes J. Ultrasound biomicroscopy of pseudophakic eyes with chronic postoperative inflammation. *J Cataract Refract Surg.* 2003; 29: 1185-91
- Park I, Lee SJ. Factors affecting precipitation of vancomycin and ceftazidime on intravitreal injection. *J Ocul Pharmacol Ther* 2013; 29: 23-6.
- Pathengay A, Flynn HW Jr, Isom RF et al. Endophthalmitis outbreaks following cataract surgery: causative organisms, etiologies, and visual acuity outcomes. *J Cataract Refract Surg* 2012; 38: 1278-82.
- Pellegrino FA, Wainberg P, Schlaen A et al. Oral clarithromycin as a treatment option in chronic post-operative endophthalmitis. *Arch Soc Esp Oftalmol* 2005; 80: 339-44.
- Perraut, L. E. Jr., Perraut, L. E., Bleiman, B. et al.: Successful treatment of *Candida albicans* endophthalmitis with intravitreal amphotericin B. *Arch Ophthalmol* 99, 1981, 1565 - 1567
- Peyman GA, Lad EM, Moshfeghi DM. Intravitreal injection of therapeutic agents. *Retina* 2009; 29: 875-912.
- Peyman, G., Lee, P., Seal, D.V. Endophthalmitis – diagnosis and management. Taylor & Francis, London: 2004, pp 1 - 270
- Peyman GA, Sathar ML, May DR. Intraocular gentamicin as intraoperative prophylaxis in South India eye camps. *Br J Ophthalmol.* 1977; 61: 260-2.
- Pflugfelder, St. C., Flynn, H. W. Jr., Zwickey, T. A., Forster, R. K., Tsiligianni, A., Culbertson, W. W., Mandelbaum, S.: Exogenous fungal endophthalmitis. *Ophthalmology* 95, 1988, 19 - 30
- Pichichero ME. Use of selected cephalosporins in penicillin-allergic patients: a paradigm shift. *Diagn Microbiol Infect Dis.* 2007 Mar;57(3 Suppl):13S-18S. Review.
- Pichichero ME, Casey JR. Safe use of selected cephalosporins in penicillin-allergic patients: a meta-analysis. *Otolaryngol Head Neck Surg.* 2007 Mar;136(3):340-7
- Pichichero ME. A review of evidence supporting the American Academy of Pediatrics recommendation for prescribing cephalosporin antibiotics for penicillin-allergic patients. *Pediatrics* 2005;115:1048
- Pichichero ME. Cephalosporins can be prescribed safely for penicillin-allergic patients. *J Fam Pract* 2006; 55: 106-12.
- Pijl BJ, Theelen T, Tilanus MA et al. Acute endophthalmitis after cataract surgery: 250 consecutive cases treated at a tertiary referral center in the Netherlands. *Am J Ophthalmol* 2010; 149: 482-487
- Pinna A, Usal D, Sechi LA, et al. An outbreak of post-cataract surgery endophthalmitis caused by *Pseudomonas aeruginosa*. *Ophthalmology* 2009;116:2321-6
- Quiroga LP, Lansingh V, Laspina F, et al. A prospective study demonstrating the effect of 5% povidone-iodine application for anterior segment intraocular surgery in Paraguay. *Arq Bras Oftalmol.* 2010 Mar-Apr;73(2):125-8.
- Råen M, Sandvik GF, Drolsum L. Endophthalmitis following cataract surgery: the role of prophylactic postoperative chloramphenicol eye drops. *Acta Ophthalmol* 2013; 91:118-22
- Rathod D, Lugmani N, Webber SK, et al. Survey of meticillin-resistant *Staphylococcus aureus* policies in UK eye departments. *J Hosp Infect* 2009; 72:314-8
- Romero-Aroca P, Méndez-Marín I, Salvat-Serra M, et al. Results at seven years after the use of intracameral cefazolin as an endophthalmitis prophylaxis in cataract surgery. *BMC Ophthalmology* 2012;12:2.
- Romero P, Méndez I, Salvat M, et al. Intracameral cefazolin as prophylaxis against endophthalmitis in cataract surgery. *J Cataract Refract Surg* 2006; 32: 438-41.

Salkind AR, Cuddy PG, Foxworth JW. The rational clinical examination. Is this patient allergic to penicillin? An evidence-based analysis of the likelihood of penicillin allergy. *JAMA* 2001;285; 2498-505

Seal, D. V., Barry, P., Gettinby, G. et al.: ESCRS study of prophylaxis of postoperative endophthalmitis after cataract surgery: Case for a European multi-centre study. *J Cataract Refract Surg.* 32, 2006, 396 – 406

Seal, D., Wright, P., Ficker, L., et al.: Placebo-controlled trial of fusidic acid gel and oxytetracycline for recurrent blepharitis and rosacea. *Br J Ophthalmol* 1995; 79: 42 - 45

Shah GK, Stein JD, Sharma S, et al. Visual outcomes following the use of intravitreal steroids in the treatment of postoperative endophthalmitis. *Ophthalmology* 2000;107: 486 – 489.

Sheng Y, Sun W, Gu Y, Lou J, Liu W. Endophthalmitis after cataract surgery in China, 1995-2009. *J Cataract Refract Surg* 2011; 37: 1715-22.

Speaker MG, Menikoff JA. Prophylaxis of endophthalmitis with topical povidone-iodine. *Ophthalmology.* 1991; 98: 1769-75.

Speaker MG, Milch FA, Shah MK, et al. Role of external bacterial flora in the pathogenesis of acute post-operative endophthalmitis. *Ophthalmology* 1991; 98: 639 – 649.

Smiddy WE, Smiddy RJ, Ba'Arath B et al. Subconjunctival antibiotics in the treatment of endophthalmitis managed without vitrectomy. *Retina* 2005; 25: 751-8.

Ta CN, Lin RC, Singh G, et al. Prospective study demonstrating the efficacy of combined preoperative three-day application of antibiotics and povidone-iodine irrigation. *Ann Ophthalmol* 2007;39:313-7

Ta CN, Singh K, Egbert PR, de Kaspar HM. Prospective comparative evaluation of povidone-iodine (10% for 5 minutes versus 5% for 1 minute) as prophylaxis for ophthalmic surgery. *J Cataract Refract Surg.* 2008 Jan;34(1):171-2

Taban M, Behrens A, Newcomb RL et al. Acute endophthalmitis following cataract surgery: a systematic review of the literature. *Arch Ophthalmol.* 2005; 123: 613-20.

Tan CS, Wong HK, Yang FP. Epidemiology of postoperative endophthalmitis in an Asian population: 11-year incidence and effect of intracameral antibiotic agents. *J Cataract Refract Surg.* 2012; 38: 425-30.

Villada JR, Vicente U, Javaloy J, et al. Severe anaphylactic reaction after intracameral antibiotic administration during cataract surgery. *J Cataract Refract Surg* 2005; 31: 620-1.

Wallin T, Parker J, Jin Y, et al. Cohort study of 27 cases of endophthalmitis at a single institution. *J Cataract Refract Surg* 2005; 31:735-41.

Warheker PT, Gupta SR, Mansfield DC, et al. Successful treatment of saccular endophthalmitis with clarithromycin. *Eye* 1998; 12: 1017-9.

Wejde G, Kugelberg M, Zetterström C. Posterior capsule opacification: comparison of 3 intraocular lenses of different materials and design. *J Cataract Refract Surg.* 2003 Aug;29(8):1556-9.

Wejde, G., Samolov, B., Seregard, S., et al.: Risk factors for endophthalmitis following cataract surgery: a retrospective case-control study. *J Hosp Infect* 61, 2005, 251 - 256.

Wisniewski SR, Capone A, Kelsey SF et al. Characteristics after cataract extraction or secondary lens implantation among patients screened for the Endophthalmitis Vitrectomy Study. *Ophthalmology* 2000; 107: 1274-1282.

Wispelway B. Clinical implications of pharmacokinetic and pharmacodynamic of fluoroquinolones. *Clin Infect Dis* 2005; Suppl 2: S127-35

Wu PC, Li M, Chang SJ, et al. Risk of endophthalmitis after cataract surgery using different protocols for povidone- iodine preoperative disinfection. *J Ocul Pharmacol Ther.* 2006 Feb;22(1):54-61

Wykoff CC, Parrott MB, Flynn HW Jr et al. Nosocomial acute-onset postoperative endophthalmitis at a university teaching hospital (2002-2009). *Am J Ophthalmol.* 2010; 150: 392-398.

Yu CQ, Ta CN. Prevention of postcataract endophthalmitis: evidence-based medicine. *Curr Opin Ophthalmol.* 2012 Jan;23(1):19-25

Yu-Wai-Man P, Morgan SJ, Hildreth AJ, et al. Efficacy of intracameral and subconjunctival cefuroxime in preventing endophthalmitis after cataract surgery. *J Cataract Refract Surg* 2008;34:447-451

Zelenitsky SA, Ariano RE, Iacovides H, et al. AUC 0-t/MIC is a continuous index of fluoroquinolone exposure and predictive of antibacterial response for *Streptococcus pneumoniae* in an in vitro infection model. *J Antimicrob Chemother* 2003;51:905-911

Additional PK/PD bibliography

Akkan AG, Mutlu I, Ozyazgan S, et al. Comparative tear concentrations of topically applied ciprofloxacin, ofloxacin, and norfloxacin in human eyes. *Int J Clin Pharmacol Ther.* 1997 May;35(5):214-7.

Akkan AG, Mutlu I, Ozyazgan S, et al. Penetration of topically applied ciprofloxacin, norfloxacin and ofloxacin into the aqueous humor of the uninflamed human eye. *J Chemother.* 1997 Aug;9(4):257-62.

Arnold DR, Granvil CP, Ward KW, Proksch JW. Quantitative determination of besifloxacin, a novel fluoroquinolone antimicrobial agent, in human tears by liquid chromatography-tandem mass spectrometry. *J Chromatogr B Analyt Technol Biomed Life Sci.* 2008 May 1;867(1):105-10.

Asbell PA, Colby KA, Deng S, et al. Ocular TRUST: nationwide antimicrobial susceptibility patterns in ocular isolates. *Am J Ophthalmol.* 2008;145:951-958.

Bucci FA. An in vivo study comparing the ocular absorption of levofloxacin and ciprofloxacin prior to phacoemulsification. *Am J Ophthalmol.* 2004 Feb;137(2):308-12.

Granvil CP, Siou-Mermet R, Comstock T, et al. Ocular pharmacokinetics of besifloxacin, a novel fluoroquinolone antimicrobial agent for topical ophthalmic use, in healthy volunteers. Poster presentation, ARVO 2008.

Hariprasad SM, Blinder KJ, Shah GK et al. Penetration pharmacokinetics of topically administered 0.5% moxifloxacin ophthalmic solution in human aqueous and vitreous. *Arch Ophthalmol.* 2005 Jan;123(1):39-44.

Holland EJ, McCarthy M, Holland S. The ocular penetration of levofloxacin 1.5% and gatifloxacin 0.3% ophthalmic solutions in subjects undergoing corneal transplant surgery. *Curr Med Res Opin.* 2007 Dec; 23(12):2955-60.

Holland EJ, Lane SS, Kim T, et al. Ocular penetration and pharmacokinetics of topical gatifloxacin 0.3% and moxifloxacin 0.5% ophthalmic solutions after keratoplasty. *Cornea.* 2008 Apr;27(3):314-9.

Katz HR, Masket S, Lane SS, et al. Absorption of topical moxifloxacin ophthalmic solution into human aqueous humor. *Cornea* 2005; 24:955-958

Kim DH, Stark WJ, O'Brien TP, et al. Aqueous penetration and biological activity of moxifloxacin 0.5% ophthalmic solution and gatifloxacin 0.3% solution in cataract surgery patients. *Ophthalmology.* 2005 Nov; 112(11):1992-6.

Koch HR, Kulus SC, Roessler M, Ropo A, Geldsetzer K (2005): Corneal penetration of fluoroquinolones: aqueous humour concentrations after topical application of levofloxacin 0.5% and ofloxacin 0.3% eyedrops. *J Cataract Refract Surg.* 31:1377-85.

Lai WW, Chu KO, Chan KP, et al. Differential aqueous and vitreous concentrations of moxifloxacin and ofloxacin after topical administration one hour before vitrectomy. *Am J Ophthalmol.* 2007;144:315-8.

McCulley JP, Caudle D, Aronowicz JD, et al. Fourth generation fluoroquinolone penetration into the aqueous humor in humans. *Ophthalmology.* 2006 Jun;113(6):955-9.

Ong-Tone L. Aqueous humor penetration of gatifloxacin and moxifloxacin eyedrops given by different methods before cataract surgery. *J Cataract Refract Surg.* 2007 Jan; 33(1):59-62.

Price MO, Quillin C, Price FW Jr. Effect of gatifloxacin ophthalmic solution 0.3% on human corneal endothelial cell density and aqueous humor gatifloxacin concentration. *Curr Eye Res.* 2005 Jul; 30(7):563-7.

Raizman MB, Rubin JM, Graves AI, et al. Tear concentrations of levofloxacin following topical administration of a single dose of 0.5% levofloxacin ophthalmic solution in healthy volunteers. *Clin Ther.* 2002 Sep;24(9):1439- 50.

Solomon R, Donnenfeld ED, Perry HD, et al. Penetration of topically applied gatifloxacin 0.3%, moxifloxacin 0.5%, and ciprofloxacin 0.3% into the aqueous humor. *Ophthalmology.* 2005 Mar;112(3):466-9.

